

# The Microfracture Technique: Pearls and Pitfalls

Devin P. Leland<sup>1</sup>, Christopher D. Bernard<sup>1</sup>, Aaron J. Krych<sup>1\*</sup>

## Abstract

Preservation of articular cartilage is essential for appropriate health and function of the knee. Chondral lesions have therefore been identified as a common cause of knee pain and morbidity. For many years, the microfracture technique has offered a simple and minimally invasive procedure for treatment of isolated articular cartilage lesions. Identifying patients who are appropriate for microfracture is difficult and requires careful selection. Younger patients (<35 years of age) with smaller lesions (<2 cm<sup>2</sup>) who are non-obese have demonstrated the greatest improvement following microfracture, especially in the short-term (<24 months). However, long-term outcomes are less promising and advanced cartilage restoration techniques such as osteochondral grafting or chondrocyte implantation have been developed. As a result, the focus of current research is centered on comparing microfracture to these more novel techniques to determine which procedure(s) offer superior long-term results. Ultimately, the orthopedist's goal has not changed since originally implementing the microfracture procedure: to provide patients with full-thickness isolated chondral defects the best available treatment for long-term preservation of knee function and biomechanics.

**Keywords:** microfracture, technique, articular cartilage, chondral lesion, knee

## Introduction

Articular cartilage functions to minimize friction, distribute compressive loads, and maintain proper function of diarthrodial joints throughout full range of motion. As a result, degeneration of articular cartilage is one of the most common causes of knee osteoarthritis, pain, and disability among middle-aged and older individuals [1]. The molecular architecture of articular cartilage is complex and essential for its purpose. Chondrocytes, the main cell type, function to produce and maintain the extracellular matrix and its components. The extracellular matrix is heterogeneous and largely composed of sulfated proteoglycans, type II collagen (hyaline cartilage), and water (> 80% of the matrix molecular weight) [2]. Proteoglycans are hydrophilic and serve the critical role of attracting water into the matrix, which due to its incompressible nature, increases the tensile

strength and load-bearing abilities of articular cartilage. Additionally, Type II collagen offers tensile strength to further protect the articular cartilage and subchondral bone from both compressive and shear forces. Each of these individual components contribute to the complex structure of articular cartilage, which functions to cushion contact surfaces and transmit articular loads with a low frictional coefficient [2].

While this complex morphology facilitates excellent joint function when healthy, it also impairs its regenerative potential and creates a challenge for restoration of damaged articular cartilage [3]. Articular cartilage is avascular and chondrocytes are able to receive nutrients and oxygen through diffusion. However, chondrocytes compose around 5% of mature joint cartilage and do not come into contact with neighboring cells, which renders them incapable of intrinsic repair when articular

cartilage is damaged [4, 5]. This understanding is imperative as chondral lesions have been reported in greater than 60% of patients undergoing knee arthroscopy, and when symptomatic, may cause significant knee pain and greatly increased risk for the development of osteoarthritis [6, 7].

The formation of fibrocartilage in repair of articular cartilage defects has been well documented, going back as early as the 1850s [8]. In 1959, Pridie published a surgical technique identifying fibrocartilage formation over chondral defects following drilling into sclerotic subchondral bone [9]. In the 1990s this procedure was modified to the more current microfracture technique; a minimally invasive, simple and cost-effective approach employing microperforations of subchondral bone to promote fibrocartilage resurfacing through angiogenesis and mesenchymal stem-cell migration [10, 11, 12, 13]. Microfracture has been the most frequently utilized surgical technique for cartilage restoration ever since. However, although fibrocartilage offers similar properties as native hyaline cartilage, it has major limitations. Fibrocartilage repair fails to reproduce the normal architecture of articular cartilage and has inferior biomechanical properties, which are less robust to stress placed on


<sup>1</sup>From the Department of Orthopedic Surgery, Mayo Clinic, Rochester, Minnesota, U.S.A.

### Address of Correspondence:

Dr Aaron J. Krych, MD  
Mayo Clinic, 200 First Street SW, Rochester, MN 55905  
Email: Krych.Aaron@Mayo.edu



Dr. Devin P. Leland



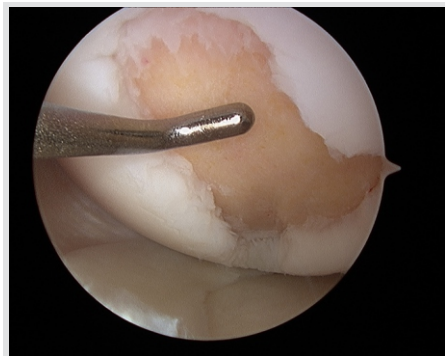Dr. Christopher D. Bernard



Dr. Aaron J. Krych

© 2019 Leland et al | Asian Journal of Arthroscopy | Available on [www.asianarthroscopy.com](http://www.asianarthroscopy.com) | doi:10.13107/aja.2456-1169.v04i01.004

This is an Open Access article distributed under the terms of the Creative Commons Attribution Non-Commercial License (<http://creativecommons.org/licenses/by-nc/3.0>) which permits unrestricted non-commercial use, distribution, and reproduction in any medium, provided the original work is properly cited.

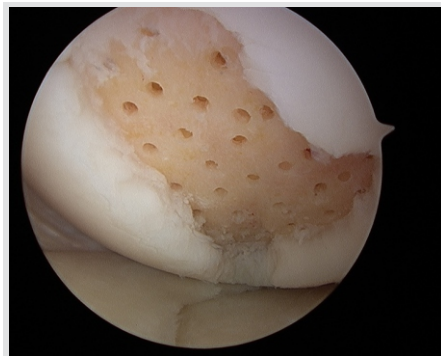


**Fig 1:** The chondral lesion is prepared arthroscopically with a stable peripheral rim of cartilage and exposed subchondral bone.

the knee joint and result in the inability to sustain suitable long-term function [3, 14].

### Indications

Identifying patients who are suitable candidates for microfracture treatment of chondral defects in the knee can be challenging. Originally, the microfracture technique was designed with the purpose of treating full-thickness chondral defects in the weightbearing areas between the femur and tibia or contact areas between the trochlear groove and patella. It was also thought to be a treatment option for both unstable cartilage lesions overlying subchondral bone and degenerative joint disease in the properly aligned knee [12, 13, 15, 16]. However, over the past 30 years as microfracture literature has developed, indications for patient selection have narrowed. Multiple factors such as anatomic location, radiographic evidence of instability, lesion size, patient age, and activity level should all be considered. Although the physical exam may differentiate anatomic location as either condylar or patellofemoral, magnetic resonance imaging (MRI) is required to pinpoint both anatomic location and lesion size. Lesion size is best estimated on MRI by identifying the largest lesion diameter between two orthogonal planes (coronal, sagittal, or axial). Younger patients (<40 years old) with a high level of knee demand should be distinguished from older patients (40-50 years old) with a lower level of knee demand. Small lesions (<2-3 cm<sup>2</sup>) in both younger, active patients and older, more sedentary patients may be candidates for treatment with microfracture. Additionally, larger lesions (>2.5-3 cm<sup>2</sup>) in older, low knee demand patients may benefit from microfracture [17, 18, 19]. Ultimately, the ideal model indication for microfracture treatment is a small, full-thickness chondral lesion in a young patient

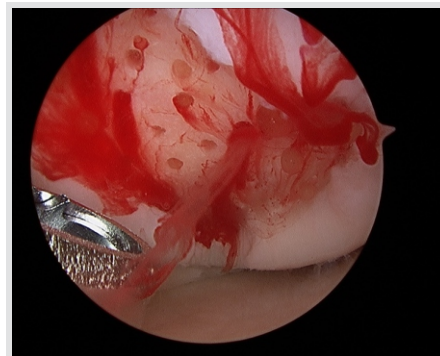


**Fig 2:** The microfracture holes have been placed perpendicular to the subchondral bone and spaced homogeneously 3-4 mm apart.

who is less than one year from initial injury [20].

A 2014 systematic review of 27 studies by Behery et al. [21] reported lesion size, location, sex, body mass index (BMI), knee alignment, and patient demand to have significant correlation with clinical outcomes following microfracture. Current research recommends microfracture as better suited for smaller lesions, although the specific size range is not exactly defined. Large lesions >4 cm<sup>2</sup> have clearly demonstrated worse outcomes following microfracture when compared to other techniques [22]. Additionally, studies have shown significantly improved patient outcomes, including return to sport, in those with smaller lesions <2 cm<sup>2</sup> [23, 24]. However, current literature is less clear for outcomes following microfracture for intermediate sized lesions, 2-4 cm<sup>2</sup>. This is most likely due to additional factors such as lesion size relative to the size of the femoral condyles, lesion location, and the local mechanical environment [25].

Furthermore, the orthopedic provider must identify and treat underlying limb malalignment or concomitant knee pathology prior to addressing the chondral defect. Meniscus pathology should be treated with repair or transplantation. Ligament instability should be reconstructed to reduce the risk of future injury to both native and restored articular cartilage. Axial malalignment requires a varus- or valgus-producing osteotomy to avoid overloading the diseased chondral surface following repair. Furthermore, in cases of patellofemoral lesions, patellar instability, tilt, and malalignment should be evaluated and addressed [20]. Additional relative contraindications to microfracture may include older age, trauma, systemic cartilage conditions, neoplastic disorders, underlying avascular necrosis, and diffuse joint



**Fig 3:** The inflow has been turned off in order to visualize the influx of blood and marrow elements. This confirms adequate depth of penetration.

degeneration [12].

### Surgical Technique

As previously mentioned, the standard microfracture technique was developed by Steadman and his colleagues as a surgical treatment for full-thickness cartilage lesions. The technique has since been extensively described as the technical simplicity and minimally invasive approach have made microfracture a commonly utilized treatment option [11, 12, 13, 26].

Diagnostic arthroscopy is performed to begin the procedure for detailed evaluation of the articular cartilage and identification of concomitant intraarticular pathology (such as meniscus or ligamentous insufficiency) which require treatment prior to addressing the chondral lesion. Once the full-thickness articular cartilage defect has been identified, unstable cartilage surrounding the lesion is debrided to stable peripheral margins utilizing a ring curette or arthroscopic shaver. Next, the calcified cartilage layer located between the subchondral bone and deep cartilage is carefully removed. Complete removal of the calcified cartilage has demonstrated to further improve the quality of tissue repair and is a critical step [27]. The surgeon must avoid excessive debridement of the subchondral bone plate, which could later result in osseous overgrowth or subchondral collapse. Utilizing an instrument that allows manual tactile feedback, such as a curette, may assist in differentiating the calcified cartilage from hard subchondral bone (Figure 1) [4]. Following removal of the calcified cartilage layer, microperforation of the subchondral bone is performed with arthroscopic awls or other commercially available pick instruments. The microfracture holes should be drilled homogeneously, beginning at the periphery of the defect before moving towards the center.

The holes are to be 1-2 mm in diameter and made perpendicular to the subchondral bone at a depth of 3-4 mm. The microfracture holes should be 3-4 mm apart to ensure adequate bone bridges for protection of the subchondral bone plate (Figure 2). After microfracture, the inflow is turned off in order to visually confirm adequate penetration via the influx of blood and marrow products (Figure 3). The released blood and marrow elements facilitate formation of a clot, all of which is necessary for stimulation of mesenchymal stem cells and proper formation of repair tissue [3].

### Rehabilitation

Rehabilitation is an important post-procedural component that must be performed both appropriately and effectively for best results. The goal of rehabilitation after microfracture is to support mesenchymal stem cell differentiation and formation of fibrocartilage repair tissue by optimizing the surrounding physical environment [16, 28]. Prior to undergoing surgery, each patient must understand that strict adherence to their rehabilitation program is critical for regaining proper functional use of the knee. Rehabilitation programs for microfracture are well documented and factors such as lesion size and location should be considered when structuring a program. Additionally, the rehabilitation program must be properly modified if concomitant knee injury is present. The two protocols outlined below have been created based upon location of the chondral lesion [11, 12, 15, 16, 26, 28].

### Femoral Condylar Lesions:

Continuous passive motion (CPM) is most commonly started immediately after the procedure due to the role it may play in facilitating increased healing of articular cartilage lesions [15, 28, 29]. The CPM machine settings should initially range from 0-70 degrees at a rate of 1 cycle per minute. CPM is performed for 6-8 hours a day 6-8 weeks following surgery, and the range of motion (ROM) may be increased by 10-20 degrees until full ROM is accomplished [15]. At 6-8 weeks, depending upon the size of the lesion, crutch-assisted partial weight bearing is permitted. Swelling and pain can be reduced with a local ice pack application in the first week post-op. Patellar mobility exercises and straight leg raises for quadriceps strength should also be started immediately post-op [3]. The senior author utilizes an antigavity

treadmill to improve patient gait mechanisms while minimizing weight bearing. As an alternative, patients may utilize a stationary bike between weeks 1-4 and deep water running at weeks 2-4 to minimize weight bearing [28]. Treadmill walking may begin at week 12 for 5-10 minutes, adding 5 minutes per session as tolerated. Body weight should be used as for resistance when beginning endurance-building exercises. Free or machine weighted muscle strength exercises may begin at month 4 if the patient is capable of proper technique. Running may also begin in a staged manner, followed by agility training, and sports and performance activities should not be started until 6 to 9 months post-op [3].

### Patellofemoral Lesions:

The angle at which the chondral lesion comes into contact with the patella or trochlear groove during active knee flexion must be noted at the time of surgery [3]. During rehabilitation extra care is required to prevent this compression from occurring [16]. Similar to femoral condylar lesions, CPM is started immediately after surgery and should range from 0-50 degrees with the same timeframe outline. A knee brace set at 0-20 degrees must be worn at all times for the first 8 weeks when not using CPM. Of note, weight bearing is allowed as tolerated as long as lesion compression is avoided, and this angle is also avoided during the strength-training phase of rehabilitation. Otherwise, the remainder of the rehabilitation program is similar to that outlined previously for femoral condylar lesions.

### Outcomes

Outcomes following microfracture for articular cartilage lesions of the knee have produced variable results. There are both patient-specific and injury specific factors which may influence the success of treatment. Multiple studies have demonstrated poor outcomes in older patients with large chondral lesions and a high BMI [17, 30, 31, 32]. Alternatively, Asik et al.[32] demonstrated significantly improved outcomes following microfracture in patients <35 years of age with full-thickness cartilage lesions <2 cm<sup>2</sup> and BMI lower than 25kg/m<sup>2</sup>. Similarly, Bae et al.[31] demonstrated that survival from future TKA was improved in lesions <2 cm<sup>2</sup> and Weber et al.[30] demonstrated that patients with a BMI >30 kg/m<sup>2</sup> had worse clinical outcomes. The differences in outcomes

amongst various patient characteristics may be attributed to the volume of repair tissue observed following microfracture. A systematic review by de Windt et al.[33] reported that more infill of the cartilage defect (higher volume of repair tissue) following microfracture to be correlated with improved clinical results. Furthermore, it has been demonstrated that a BMI >30 kg/m<sup>2</sup> and patient age > 40 years are both correlated with decreased infill volume [26, 34]. Although the data is limited, anatomic location of the lesion has also been reported to affect microfracture outcomes. A prospective study by Kreuz et al.[35] reported patients with a femoral condyle lesion to have significantly greater outcomes when compared with patients treated for a chondral lesion of the trochlea, tibia, and patella. Another study by de Windt et al.[36] demonstrated lateral femoral condylar defects to have worse outcomes than medial femoral condylar defects. Age of the chondral lesion should also be considered as older defects, such as those present for >18 months, have demonstrated worse outcomes [34, 36].

Clinical outcomes following microfracture of the knee have demonstrated very promising results at short-term follow-up, yet long-term studies have not revealed nearly as positive results. A systematic review by Mithoefer et al.[19], which included 28 studies and 3122 patients, demonstrated short-term ( $\leq$  24 months) clinical improvement in 75-100% of patients following microfracture of the knee. Conversely, at long-term follow-up (>24 months), clinical improvement was seen in 67-87% of patients and 47-80% demonstrated functional deterioration. Similarly, in a long-term outcomes study, Solheim et al.[37] reported significant improvement in Lysholm scores at 12 months follow-up when compared to baseline. However, at a median 5 years, median 10 years, and minimum 15 years follow-up the Lysholm scores had successively declined. The rate of return to sport following microfracture of the knee has also varied among studies, but is generally favorable in the short-term. A 2017 meta-analysis by Krych et al.[38] reported a return to sport in 45-80% of patients at an average of 9.1 months following surgery for cartilage injuries of the knee. However, similar to the trend observed in outcome scores, a decline in sports activity level may be observed over time [39].

### Subchondral Drilling

Although subchondral drilling may have

advantages over microfracture, its use has been limited and few studies have directly compared the two techniques. Much of the concern surrounding this technique was due to the theoretical risk of thermal damage to subchondral bone with use of a motorized drill, leading to necrosis and collapse. However, this concern may be alleviated with the use of irrigation. In a rabbit model of knee cartilage lesions, Chen et al.[40] reported that while microfracture generates holes for repair, the surrounding bone was fractured and compacted bone, essentially sealing off and potentially impeding the influx of viable bone marrow for repair. Conversely, drilling was reported to effectively remove bone from the holes and provide channels of access to the marrow stroma. In a separate rabbit study, Chen et al.[41] compared microfracture at a depth of 2 mm to subchondral drilling at both 2 mm and 6 mm depths. This study reported that subchondral drilling to a depth of 6 mm resulted in a chondral lesion with significantly greater fill and hyaline composition when compared to microfracture at 2 mm. These findings may be due to a greater influx of bone marrow stem cells, which has been demonstrated to correlate strongly with the quality of cartilage repair tissue due to their clonogenic, chondrogenic, and matrix production potentials [42].

Subchondral drilling may also offer improved cartilage regeneration by allowing for augmentation with other treatments. Saw et al.[43] investigated the outcomes of patients with chondral lesions of the knee who underwent subchondral drilling augmented with injections of either autologous peripheral blood stem cells or hyaluronic acid. Their study demonstrated superior histologic and radiographic results in the cohort with combined subchondral drilling and peripheral blood stem cell injection compared to drilling alone; however, subjective IKDC scores were reported similar between the two groups.

### Chondral Grafting

As a result of the desire to improve patient outcomes and orthopedic practice, novel cartilage restoration techniques such as osteochondral autograft transplantation (OAT), osteochondral allograft transplantation (OCA), autologous chondrocyte implantation (ACI), and matrix-induced chondrocyte implantation (MACI) have been more recently developed. Long-term outcomes with comparison to

microfracture have resulted in a shift away from utilizing the microfracture technique in many circumstances; However, a definitive conclusion on the optimal cartilage restoration technique remains. When comparing mosaicplasty to microfracture, a 2018 study by Solheim et al.[37] reported mosaicplasty to demonstrate superior clinical outcomes at short, medium, and long-term follow-up. A 2017 meta-analysis by Riboh et al.[44] comparing several surgical treatments for chondral defects of the knee demonstrated similar functional outcomes and re-operation rates at two years for both microfracture and advanced repair techniques. However, advanced repair techniques such as OAT, ACI, and MACI resulted in higher-quality repair tissue which may improve outcomes and lower re-operation rates in the long-term. Similarly, a systematic review by Devitt et al.[45] demonstrated microfracture as equivalent or inferior to OAT, MACI, and ACI, yet never superior.

When evaluating return to sport, a prospective, randomized level I study by Gudas et al.[46] comparing mosaicplasty to microfracture in athletes reported the OAT technique to have a higher rate of return to and maintenance of sports at the preinjury level when compared to microfracture. In regards to histologic outcomes, a meta-analysis evaluating various treatments of knee chondral lesions by DiBartola et al.[47] reported microfracture to be inferior compared to other techniques, such as OATS and ACI. While the repair tissue after microfracture was primarily fibrocartilage, repair tissue following OAT contained a larger amount of type II (hyaline) cartilage. Although the amount of fibrocartilage increased over time following microfracture, no improvement in tissue quality was observed. Alternatively, an increase in hyaline-like tissue was observed over time as tissue maturation progressed following ACI.

### Debridement

Debridement of articular cartilage defects has also been well documented and studied over the years, although studies comparing the outcomes of debridement and microfracture are more limited. In a 2018 prospective study, Ulstein et al.[48] reported on 368 patients who underwent microfracture, debridement, or no concomitant procedure for full-thickness articular cartilage damage at the time of primary anterior cruciate ligament reconstruction (ACLR). Their study

demonstrated no significant difference in KOOS scores at 5-year follow-up between the debridement-ACLR, microfracture ACLR, and cartilage lesions left untreated at the time of ACLR. Similarly, Gudas et al.[49] reported no significant difference in outcomes between cohorts who underwent microfracture-ACLR and debridement-ACLR. However, significantly improved IKDC scores were observed in the OAT-ACLR group versus microfracture or debridement at 3-year follow-up. Due to study results such as those mentioned above, many clinicians have the strong opinion that there is no indication for microfracture of isolated articular cartilage lesions as debridement provides similar results [50].

### Complications

Complications due to microfracture are rare due in large part to the technical simplicity and minimally invasive approach of the procedure. A 2019 study investigating complication rates following treatment of chondral lesions of the knee found a complication rate of 1.5% following microfracture [51]. Potential complications of microfracture include fracture of subchondral bridges, bony or hypertrophic overgrowth, or incomplete microfracture with limited influx of marrow elements [20]. As previously mentioned, it is important to avoid excessive debridement of the subchondral bone plate, as this may later result in fragmentation or delamination of the fibrocartilage-subchondral bone junction [27]. When comparing microfracture, OAT, OCA, and ACI, no statistically significant difference in overall complication rates has been reported [51].

## Conclusions & Keypoints

The microfracture procedure has been offered for many years as a simple and minimally invasive technique for treatment of isolated chondral defects of the knee. Identifying patients who are suitable for treatment is difficult and requires careful selection. Younger patients (<35 years of age) with smaller lesions (<2 cm<sup>2</sup>) who are non-obese have demonstrated the most improvement following microfracture, especially in the short-term (<24 months). However, long-term outcomes are less favorable and novel cartilage restoration techniques such as chondral grafting or chondrocyte implantation have been developed. As result, the

focus of current research is centered on comparing these advanced cartilage restoration techniques with microfracture to determine which procedures offer superior long-term results. Ultimately, the orthopedist's goal has not changed since original implementation of the microfracture procedure: to offer patients full-thickness isolate chondral defects the best available treatment in effort to preserve knee function and biomechanics long-term.

## References

- Buckwalter JA, Mankin HJ. Articular cartilage: degeneration and osteoarthritis, repair, regeneration, and transplantation. Instructional course lectures. 1998;47:487-504.
- Sophia Fox AJ, Bedi A, Rodeo SA. The Basic Science of Articular Cartilage: Structure, Composition, and Function. Sports Health. 2009;1(6):461-68.
- Ansari MH, Sousa PL, Stuart MJ, Krych AJ. Microfracture in review: Careful evaluation and patient selection are paramount for treatment of articular cartilage lesions of the knee. Minerva Ortopedica e Traumatologica. 2015;66(2):87-100.
- Case JM, Scopp JM. Treatment of Articular Cartilage Defects of the Knee With Microfracture and Enhanced Microfracture Techniques. Sports medicine and arthroscopy review. 2016;24(2):63-8.
- Richter W. Mesenchymal stem cells and cartilage in situ regeneration. Journal of internal medicine. 2009;266(4):390-405.
- Curl WW, Krome J, Gordon ES, Rushing J, Smith BP, Poehling GG. Cartilage injuries: a review of 31,516 knee arthroscopies. Arthroscopy : the journal of arthroscopic & related surgery : official publication of the Arthroscopy Association of North America and the International Arthroscopy Association. 1997;13(4):456-60.
- Gelber AC, Hochberg MC, Mead LA, Wang NY, Wigley FM, Klag MJ. Joint injury in young adults and risk for subsequent knee and hip osteoarthritis. Annals of internal medicine. 2000;133(5):321-8.
- Redfern P. On the healing of wounds in articular cartilage. Month J Med Sci. 1851;13:201-02.
- Pridie KH. The method of resurfacing osteoarthritic knee joints. J Bone Joint Surgery Br. 1959;41:618-23.
- Blevins F, Steadman J, Rodrigo J. Treatment of articular cartilage defects in athletes: An analysis of functional outcome and lesion appearance. Orthopedics. 1998;21(7):761-68.
- Mithoefer K, Steadman JR. The Microfracture Technique. Techniques in Knee Surgery. 2006;5(3):140-48.
- Steadman JR, Rodkey WG, Rodrigo JJ. Microfracture: surgical technique and rehabilitation to treat chondral defects. Clinical orthopaedics and related research. 2001(391 Suppl):S362-9.
- Steadman JR, Rodkey WG, Briggs KK. Microfracture Chondroplasty: Indications, Techniques, and Outcomes. Sports medicine and arthroscopy review. 2003;11(4):236-44.
- Frisbie DD, Oxford JT, Southwood L, Trotter GW, Rodkey WG, Steadman JR, et al. Early events in cartilage repair after subchondral bone microfracture. Clinical orthopaedics and related research. 2003(407):215-27.
- Rodrigo JJ, Steadman JR, Silliman JF, Fulstone HA. Improvement of full-thickness chondral defect healing in the human knee after debridement and microfracture using continuous passive motion. The American journal of knee surgery. 1994;7(3):109-16.
- Steadman JR, Rodkey WG, Briggs KK. Microfracture to treat full-thickness chondral defects: surgical technique, rehabilitation, and outcomes. J Knee Surg. 2002;15(3):170-6.
- Steadman JR, Briggs KK, Rodrigo JJ, Kocher MS, Gill TJ, Rodkey WG. Outcomes of microfracture for traumatic chondral defects of the knee: average 11-year follow-up. Arthroscopy : the journal of arthroscopic & related surgery : official publication of the Arthroscopy Association of North America and the International Arthroscopy Association. 2003;19(5):477-84.
- Knutsen G, Drogset JO, Engebretsen L, Grontvedt T, Isaksen V, Ludvigsen TC, et al. A randomized trial comparing autologous chondrocyte implantation with microfracture. Findings at five years. The Journal of bone and joint surgery American volume. 2007;89(10):2105-12.
- Mithoefer K, McAdams T, Williams RJ, Kreuz PC, Mandelbaum BR. Clinical efficacy of the microfracture technique for articular cartilage repair in the knee: an evidence-based systematic analysis. The American journal of sports medicine. 2009;37(10):2053-63.
- Camp CL, Stuart MJ, Krych AJ. Current concepts of articular cartilage restoration techniques in the knee. Sports Health. 2014;6(3):265-73.
- Behery O, Siston RA, Harris JD, Flanigan DC. Treatment of cartilage defects of the knee: expanding on the existing algorithm. Clin J Sport Med. 2014;24(1):21-30.
- Knutsen G, Engebretsen L, Ludvigsen TC, Drogset JO, Grontvedt T, Solheim E, et al. Autologous chondrocyte implantation compared with microfracture in the knee. A randomized trial. The Journal of bone and joint surgery American volume. 2004;86-a(3):455-64.
- Gudas R, Kalesinskas RJ, Kimtys V, Stankevicius E, Toličius V, Bernotavicius G, et al. A prospective randomized clinical study of mosaic osteochondral autologous transplantation versus microfracture for the treatment of osteochondral defects in the knee joint in young athletes. Arthroscopy. 2005;21(9):1066-75.
- Mithoefer K, Williams RJ, 3rd, Warren RF, Wickiewicz TL, Marx RG. High-impact athletics after knee articular cartilage repair: a prospective evaluation of the microfracture technique. The American journal of sports medicine. 2006;34(9):1413-8.
- Sommerfeldt MF, Magnussen RA, Hewett TE, Kaeding CC, Flanigan DC. Microfracture of Articular Cartilage. JBJS reviews. 2016;4(6).
- Mithoefer K, Williams RJ, 3rd, Warren RF, Potter HG, Spock CR, Jones EC, et al. The microfracture technique for the treatment of articular cartilage lesions in the knee. A prospective cohort study. The Journal of bone and joint surgery American volume. 2005;87(9):1911-20.
- Frisbie DD, Trotter GW, Powers BE, Rodkey WG, Steadman JR, Howard RD, et al. Arthroscopic subchondral bone plate microfracture technique augments healing of large chondral defects in the radial carpal bone and medial femoral condyle of horses. Veterinary surgery : VS. 1999;28(4):242-55.
- Hurst JM, Steadman JR, O'Brien L, Rodkey WG, Briggs KK. Rehabilitation following microfracture for chondral injury in the knee. Clinics in sports medicine. 2010;29(2):257-65, viii.
- Williams JM, Moran M, Thonar EJ, Salter RB. Continuous passive motion stimulates repair of rabbit knee articular cartilage after matrix proteoglycan loss. Clinical orthopaedics and related research. 1994(304):252-62.
- Weber AE, Locker PH, Mayer EN, Cvetanovich GL, Tilton AK, Erickson BJ, et al. Clinical Outcomes After Microfracture of the Knee: Midterm Follow-up. Orthopaedic journal of sports medicine. 2018;6(2):2325967117753572.
- Bae DK, Song SJ, Yoon KH, Heo DB, Kim TJ. Survival analysis of

- microfracture in the osteoarthritic knee-minimum 10-year follow-up. *Arthroscopy : the journal of arthroscopic & related surgery : official publication of the Arthroscopy Association of North America and the International Arthroscopy Association*. 2013;29(2):244-50.
32. Asik M, Ciftci F, Sen C, Erdil M, Atalar A. The microfracture technique for the treatment of full-thickness articular cartilage lesions of the knee: midterm results. *Arthroscopy : the journal of arthroscopic & related surgery : official publication of the Arthroscopy Association of North America and the International Arthroscopy Association*. 2008;24(11):1214-20.
  33. de Windt TS, Welsch GH, Brittberg M, Vonk LA, Marlovits S, Trattnig S, et al. Is magnetic resonance imaging reliable in predicting clinical outcome after articular cartilage repair of the knee? A systematic review and meta-analysis. *The American journal of sports medicine*. 2013;41(7):1695-702.
  34. Kreuz PC, Erggelet C, Steinwachs MR, Krause SJ, Lahm A, Niemeyer P, et al. Is microfracture of chondral defects in the knee associated with different results in patients aged 40 years or younger? *Arthroscopy : the journal of arthroscopic & related surgery : official publication of the Arthroscopy Association of North America and the International Arthroscopy Association*. 2006;22(11):1180-6.
  35. Kreuz PC, Steinwachs MR, Erggelet C, Krause SJ, Konrad G, Uhl M, et al. Results after microfracture of full-thickness chondral defects in different compartments in the knee. *Osteoarthritis Cartilage*. 2006;14(11):1119-25.
  36. de Windt TS, Bekkers JE, Creemers LB, Dhert WJ, Saris DB. Patient profiling in cartilage regeneration: prognostic factors determining success of treatment for cartilage defects. *The American journal of sports medicine*. 2009;37 Suppl 1:58s-62s.
  37. Solheim E, Hegna J, Strand T, Harlem T, Inderhaug E. Randomized Study of Long-term (15-17 Years) Outcome After Microfracture Versus Mosaicplasty in Knee Articular Cartilage Defects. *The American journal of sports medicine*. 2018;46(4):826-31.
  38. Krych AJ, Pareek A, King AH, Johnson NR, Stuart MJ, Williams RJ, 3rd. Return to sport after the surgical management of articular cartilage lesions in the knee: a meta-analysis. *Knee surgery, sports traumatology, arthroscopy : official journal of the ESSKA*. 2017;25(10):3186-96.
  39. Gobbi A, Nunag P, Malinowski K. Treatment of full thickness chondral lesions of the knee with microfracture in a group of athletes. *Knee surgery, sports traumatology, arthroscopy : official journal of the ESSKA*. 2005;13(3):213-21.
  40. Chen H, Sun J, Hoemann CD, Lascau-Coman V, Ouyang W, McKee MD, et al. Drilling and microfracture lead to different bone structure and necrosis during bone-marrow stimulation for cartilage repair. *Journal of orthopaedic research : official publication of the Orthopaedic Research Society*. 2009;27(11):1432-8.
  41. Chen H, Hoemann CD, Sun J, Chevrier A, McKee MD, Shive MS, et al. Depth of subchondral perforation influences the outcome of bone marrow stimulation cartilage repair. *Journal of orthopaedic research : official publication of the Orthopaedic Research Society*. 2011;29(8):1178-84.
  42. Dwivedi G, Chevrier A, Alameh MG, Hoemann CD, Buschmann MD. Quality of Cartilage Repair from Marrow Stimulation Correlates with Cell Number, Clonogenic, Chondrogenic, and Matrix Production Potential of Underlying Bone Marrow Stromal Cells in a Rabbit Model. *Cartilage*. 2018;1947603518812555.
  43. Saw KY, Anz A, Siew-Yoke Jee C, Merican S, Ching-Soong Ng R, Roohi SA, et al. Articular cartilage regeneration with autologous peripheral blood stem cells versus hyaluronic acid: a randomized controlled trial. *Arthroscopy : the journal of arthroscopic & related surgery : official publication of the Arthroscopy Association of North America and the International Arthroscopy Association*. 2013;29(4):684-94.
  44. Riboh JC, Cvetanovich GL, Cole BJ, Yanke AB. Comparative efficacy of cartilage repair procedures in the knee: a network meta-analysis. *Knee surgery, sports traumatology, arthroscopy : official journal of the ESSKA*. 2017;25(12):3786-99.
  45. Devitt BM, Bell SW, Webster KE, Feller JA, Whitehead TS. Surgical treatments of cartilage defects of the knee: Systematic review of randomised controlled trials. *The Knee*. 2017;24(3):508-17.
  46. Gudas R, Gudaite A, Pocius A, Gudiene A, Cekanauskas E, Monastyreckiene E, et al. Ten-year follow-up of a prospective, randomized clinical study of mosaic osteochondral autologous transplantation versus microfracture for the treatment of osteochondral defects in the knee joint of athletes. *The American journal of sports medicine*. 2012;40(11):2499-508.
  47. DiBartola AC, Everhart JS, Magnussen RA, Carey JL, Brophy RH, Schmitt LC, et al. Correlation between histological outcome and surgical cartilage repair technique in the knee: A meta-analysis. *The Knee*. 2016;23(3):344-9.
  48. Ulstein S, Aroen A, Engebretsen L, Forssblad M, Lygre SHL, Rotterud JH. A Controlled Comparison of Microfracture, Debridement, and No Treatment of Concomitant Full-Thickness Cartilage Lesions in Anterior Cruciate Ligament-Reconstructed Knees: A Nationwide Prospective Cohort Study From Norway and Sweden of 368 Patients With 5-Year Follow-up. *Orthopaedic journal of sports medicine*. 2018;6(8):2325967118787767.
  49. Gudas R, Gudaite A, Mickevicius T, Masiulis N, Simonaityte R, Cekanauskas E, et al. Comparison of osteochondral autologous transplantation, microfracture, or debridement techniques in articular cartilage lesions associated with anterior cruciate ligament injury: a prospective study with a 3-year follow-up. *Arthroscopy : the journal of arthroscopic & related surgery : official publication of the Arthroscopy Association of North America and the International Arthroscopy Association*. 2013;29(1):89-97.
  50. Bert JM. Abandoning microfracture of the knee: has the time come? *Arthroscopy : the journal of arthroscopic & related surgery : official publication of the Arthroscopy Association of North America and the International Arthroscopy Association*. 2015;31(3):501-5.
  51. Gowd AK, Cvetanovich GL, Liu JN, Christian DR, Cabarcas BC, Redondo ML, et al. Management of Chondral Lesions of the Knee: Analysis of Trends and Short-Term Complications Using the National Surgical Quality Improvement Program Database. *Arthroscopy : the journal of arthroscopic & related surgery : official publication of the Arthroscopy Association of North America and the International Arthroscopy Association*. 2019;35(1):138-46.

Conflict of Interest: NIL

Source of Support: NIL

#### How to Cite this Article

Leland DP, Bernard CD, Krych AJ. The Microfracture Technique: Pearls and Pitfalls. *Asian Journal Arthroscopy*. Jan-April 2019;4(1):9-14.