

Scaffold based Autologous Chondrocyte Implantation: The Surgical Technique

Mats Brittberg¹

Abstract

Autologous chondrocyte implantation (ACI) has been used clinically since 1987. Most reports on ACI are on the first and second generation ACI with cells in suspension under a sutured membrane and performed with open surgery. Today's 3rd and 4th generation ACI with cells seeded and grown in or on scaffolds prior to implantation opens up for transarthroscopic implantations. Transarthroscopic surgery reduces the morbidity for the patients and also fastens up the rehab process. In this paper, techniques used for scaffold based ACI are presented.

Keywords: Autologous chondrocyte implantation, generations, scaffolds

Introduction

As cartilage has a poor ability for self-repair, articular cartilage lesions have become an important target for tissue engineering. Many techniques to improve the repairs of injured articular cartilage surfaces have been used the last 60 years but articular cartilage defect repair is still a major challenge.

Important to understand in order to perform good quality cartilage repair are the following knowledge:

- The repair induction is cell density dependent
 - Cell choice could be via intrinsic or extrinsic sources.
 - The articular chondrocytes alone are responsible for the specific features of articular cartilage and therefore it seems rationale to use true committed chondrocytes to repair a cartilaginous defect [1, 2].
- In this presentation, I will focus on the use of 3rd and 4th generation Autologous Chondrocyte implantation (ACI).

Autologous Chondrocyte implantation (ACI)

Autologous Chondrocyte implantation (ACI) was first performed clinically in a knee in Gothenburg, Sweden in 1987 (1). It was the 1st generation ACI with chondrocytes in cell suspension implanted beneath a membrane of periosteum sutured around the defect area. After some years, the second generation ACI was introduced where the periosteum was exchanged with a membrane out of collagen. The 3rd generation ACI all use a scaffold where the cells have been cultured either on the surface of the scaffold or in the pores of the scaffold.

The 4th generation ACI also uses scaffolds but here the cells are used and seeded as one stage procedures.

Indications:

The main indication is defects larger than 3cm². The second indication is all sizes of lesions that have failed earlier cartilage treatment
ACI could also be combined with concomitant repair of subchondral bone

defects.

To be successful in cartilage repair with ACI concomitant injuries/defects must be taken care of at same time as ACI is performed.

Such concomitant injuries/defects are:

- Patella instability
- Ligament insufficiency
- Angular deformities.

The ACI harvest procedure:

Cartilage slices are harvested from a minor weight bearing area in the knee. The biopsies are sent to a lab for enzymatic cell isolation and expansion for about 1 week before the cells are seeded on or into the scaffold material for further culture about 3-4 weeks.

3rd Generation ACI:

The 3rd generation of ACI with cells used together with matrices could be divided into three categories:

1. Chondrocyte seeded matrices with cells grown within the scaffold's pores and fibres [3].
2. Chondrocyte seeded carriers with cells growing on the surface of the material. The cells are migrating from the matrice after delivery to the defect area [4].
3. Chondrocytes seeded on a scaffolding material just prior to implantation [5].

The 4th generations of ACI are one stage procedures and could also be divided into three categories:

¹ Cartilage Research Unit, University of Gothenburg, Region Halland Orthopaedics, Kungälv Hospital, S-434 80 Kungälv Sweden.

Address of Correspondence:

Professor Mats Brittberg
Cartilage Research Unit, University of Gothenburg, Region Halland Orthopaedics, Kungälv Hospital, S-434 80 Kungälv Sweden.
Email: Mats.brittberg@telia.com



Professor Mats Brittberg

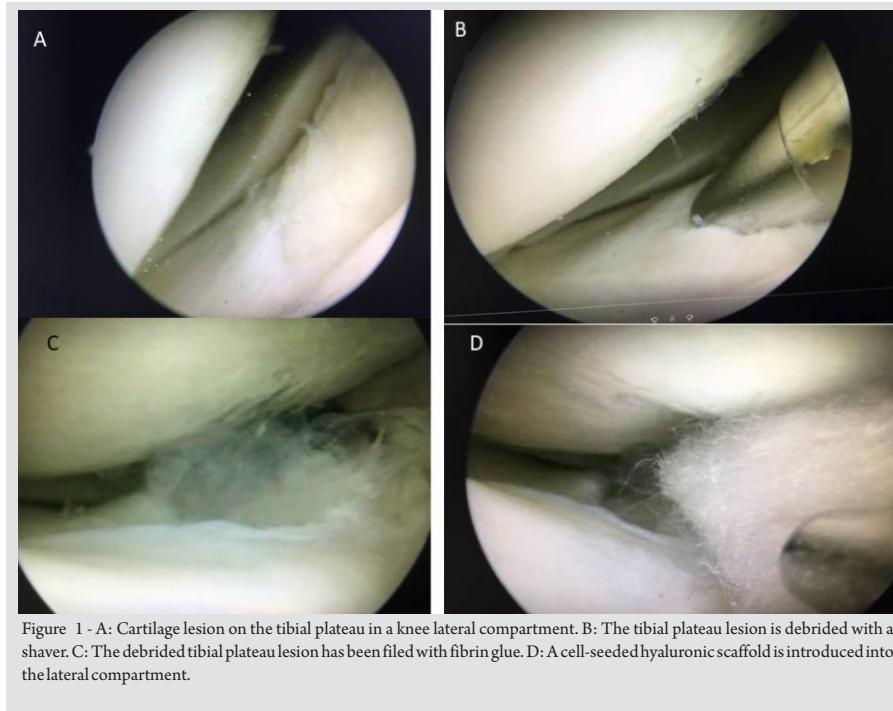


Figure 1 - A: Cartilage lesion on the tibial plateau in a knee lateral compartment. B: The tibial plateau lesion is debrided with a shaver. C: The debrided tibial plateau lesion has been filled with fibrin glue. D: A cell-seeded hyaluronic scaffold is introduced into the lateral compartment.

1. Direct isolation of chondrocytes, non-expanded and mixed with directly isolated autologous MSCs seeded on a matrix just prior to implantation [6].
2. Direct isolation of chondrons mixed with allograft chondrocytes [7].
3. Harvest of cartilage that is morselized and put on to a membrane in small fragments covered with fibrin glue for re-implantation. In the defect area, the most active cells are migrating out from the membrane into a layer of fibrin glue [8].

Operative Technical variants.

Today, most surgeons are using third generation ACI with cells on cell carriers or in cell seeded scaffolds [9,10]. The scaffold based ACI just need to be fixated with fibrin glue and when performed by open surgery the implantation could most often be done via mini-incisions. However, most of the 3rd generation ACI techniques are used transarthroscopically together with pressure controlled pumps using saline to produce a distension of the joints. Some transarthroscopic graft positioning is difficult to perform with a constant flow of saline and the inflow sometimes needs to be reduced or stopped. The disadvantage is that the joint capsule may then collapse and the sight for implantation will be reduced. It is also possible to do the implantations using arthroscopy with Carbon dioxide [11].

Chondrocytes grown inside a scaffold (3rd generation ACI type 1)

As an example of a Type 1 Scaffold-ACI, Hyaff-11 scaffold is here presented. A Hyaff-11 membrane is allowing the chondrocytes to grow inside the porous material and could be implanted by press fitting directly into the lesion as described by Marcacci et al. [12]. The scaffold has self-adhesive properties but most often additional fibrin glue is needed for a secure positioning. A modified implantation technique; the "folded blanket" technique for the knee is here described below [9].

Cartilage biopsies are harvested as described for Generation 1 above from a minor weight bearing area and sent to the cell laboratories. After 4-5 weeks, the scaffold is delivered as 2 x 2 cm large patches. Anteromedial or anterolateral portals are created and an arthroscopy is performed in supine position. For a defect at the medial femoral condyle an anteromedial suprameniscal portal is created. The chondrocyte seeded matrix is prepared with a scissor or scalpel to an appropriate size of the defect.

The lesion is filled with a layer of fibrin glue at the bottom with a syringe. The scaffold is caught with an arthroscopic grasper with plain surfaces and introduced into the joint using a half pipe instrument to reach the defect. The scaffold is released and pushed with the smooth troacar into the fibrin glue covered debrided lesion area. Some extra

fibrin glue is injected over the implanted graft and the graft is compressed towards the defect bottom with a curved tonsil elevator. If the scaffold is oversized, the edges may be folded like a blanket into the defect to fill it up entirely; the folded blanket technique [9]. If the defect is very large, more cut pieces of the scaffold are implanted to fill the defect like a patchwork quilt. Several layers of the cell seeded hyaluronic graft may be needed to fill the defect up to surrounding cartilage; the mille feuille technique [9].

Graft position stability is controlled by flexion and extension movements. The scaffold should either be in level with surrounding cartilage or slightly below.

Knee implantation of a cell seeded collagen carrier, 3rd generation ACI type 2 (14).

The same type of debridement is used as for type 1 grafts. Here one needs more precise measurement of the lesion as the scaffold cannot be folded. The size of the defect is measured with a ruler and the measurements are used to shape the membrane to get exact the size of the measured defect. The defect bottom is filled with fibrin glue.

As on a cell carrier, the cells are grown just on the surface of one side of the scaffold material coloured dots need to be placed onto the cell side to guide the orientation once the graft is inside the knee. The cell seeded graft is introduced into the knee via an arthroscopic cannula like a half pipe instrument.

The graft is positioned into the defect using a probe with care to get the cell side of the membrane the right way up. Fibrin glue is finally injected over the exact fitted implant.

Knee implantation of a membrane that has been seeded with chondrocytes just prior to implantation. 3rd Generation ACI type [5].

Most often a collagen I and III membrane is used and the upper porous layer is then seeded with the cultured chondrocytes, to a minimum density of Knee implantation of a membrane that has been seeded with chondrocytes just prior to implantation. 3rd Generation ACI type [5]. Most often a collagen I and III membrane is used and the upper porous layer is then seeded with the cultured chondrocytes, to a minimum density of 106 cells/cm. During a 10-minute incubation period at room temperature, the chondrocytes are to adhere to the porous

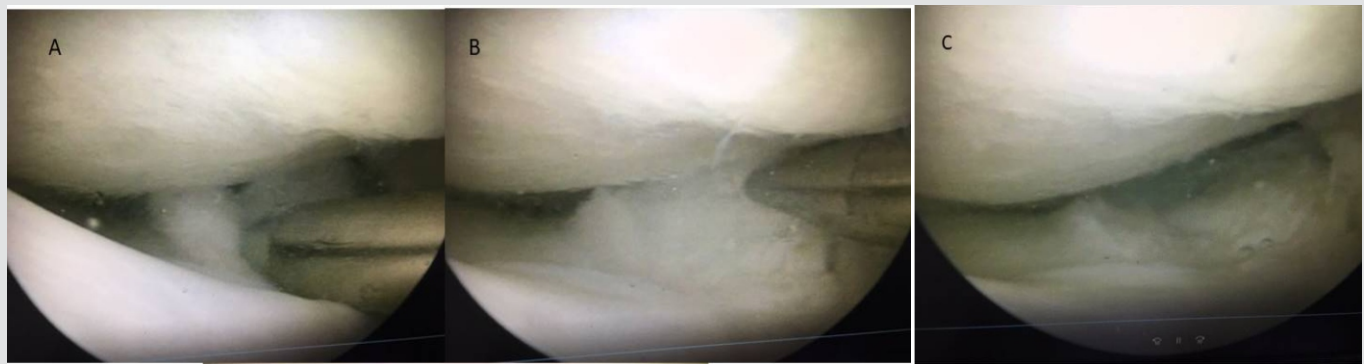

Figure 2- A: The cell seeded hyaluronic acid graft is pushed into the cartilage fibrin filled lesion with an arthroscopic probe. B: The cell seeded graft has now been positioned in the lesion and is smoothed with a curved tonsil elevator. C: The cell seeded graft's stability has been tested by flexion-extension motions of the joint and no tendency for dislocation.

layer and the seeded membrane can then finally be introduced into the defect. The seeded porous layer, is placed on the bone bottom surface filled with fibrin glue like what is done with ACI type 2. Finally, the top of the membrane is fixated with fibrin glue even though some doctors add sutures if the procedure has been done as open surgery.

Implantation techniques using the 4th Generation of ACI

Fourth generation ACI Type 1 is done with direct isolation of chondrocytes, non-expanded mixed with direct isolated autologous MSCs seeded on a matrix just prior to implantation [6]. A special automated cell processor extracts the different cell types from cartilage and bone marrow biopsies respectively in the operating room. The processor then seeds the cells into a porous scaffold for direct one stage implantation. In the type 2 4th generation [7] instead debrided cartilage lesion tissue is recycled using a rapid enzymatic isolation protocol to obtain 100,000–400,000 chondrons (chondrocytes with their pericellular matrix). Allogeneic cryopreserved passage 3 bone marrow-derived MSCs are then mixed with the chondrons. The cell composition is finally suspended in fibrin glue and implanted into the defect area. Approximately 0.9 ml cell product per square centimeter defect was

implanted [7].

Technique with morselized cartilage put on a membrane for implantation

With the knowledge that chondrocytes with high activity could migrate out from a fragmented piece of cartilage, the cartilage autograft implantation system-CAIS was developed (8). Cartilage fragments are harvested from minor weight bearing areas of the joint and are morselized into mini-pieces and seeded on a resorbable membrane covered with fibrin glue.

The cartilage fragment- membrane composition is introduced via mini-arthrotomy or transarthroscopic into the lesion area and fixated with resorbable staples.

Postoperative Rehabilitation

The rehabilitation protocols follow the same guidelines as used for open procedure ACI. However, as the patients most often experience less morbidity due to the less invasive nature of the operation, the patients need to be informed quite carefully of the maturing process of cartilage implants. The maturing process for a cartilage graft may take between 1-4 years.

A practical rehab protocol that can be used for different repair techniques of the knee includes the following steps:

- a brace locking the knee joint in extension used for two weeks
- followed by the unlocking of the brace to allow the brace to become a side stabilizing brace for another 4 weeks used only outdoors.
- With the brace, the patients could be allowed full weight bearing as long as the defects are well shouldered.
- Return to sports is most often for intensive contact sports around 12 months while individual start of running starts between 7-9 months.

The above rehab is quite aggressive but Della Villa et al. (2010) have shown that an intensive rehabilitation may safely allow a faster return to competition in athletes and also influence positively the clinical outcome at a medium-term follow-up. The same faster rehab may also subsequently be used by non-athletes but more individualized [12].

Conclusions & Keypoints

Still most of all types of ACI are done by open surgery. However, with the introduction of 3rd and 4th generation ACI with cells seeded in and on membranes or cultured in matrices, the implantation can be done transarthroscopically and the technique could be used for all types of joints with cartilage injuries.

References

1. Brittberg M, Lindahl A, Nilsson A et al. Treatment of deep cartilage defects in the knee with autologous chondrocyte transplantation. *New England Journal of Medicine* 1994; 331:889-895.
2. Brittberg M. Cartilage repair. On cartilaginous tissue engineering with the emphasis on chondrocyte transplantation. Thesis. University of Gothenburg. 1996.
3. Brittberg M. Cell carriers as the next generation of cell therapy for cartilage repair: a review of the matrix-induced autologous chondrocyte implantation procedure. *Am J Sports Med.* 2010; Jun;38(6):1259-71.
4. Steinwachs M. New technique for cell-seeded collagen-matrix-supported autologous chondrocyte transplantation. *Arthroscopy.* 2009; Feb;25(2):208-11.
5. Hendriks JA, Moroni L, Riesle et al. The effect of scaffold-cell entrapment capacity and physico-chemical properties on cartilage regeneration. *Biomaterials.* 2013 Jun;34(17):4259-65
6. de Windt TS, Vonk LA, Slaper-Cortenbach ICM, Nizak R, van Rijen MHP, Saris DBF. Allogeneic MSCs and Recycled Autologous Chondrons Mixed in a One-Stage Cartilage Cell Transplantation: A First-in-Man Trial in 35 Patients. *Stem Cells.* 2017 Aug;35(8):1984-1993
7. Brittberg M. Cartilage fragment implantation. . In *Cartilage Surgery. An operative manual.* Eds Brittberg M, Gersoff W. Elsevier Saunders Philadelphia, 2011; 181-191.
8. Brittberg M, Concaro S. Transarthroscopic implantation of Hyalograft (Hyaff 11) with autologous chondrocytes. In *Cartilage Surgery. An operative manual.* Eds Brittberg M, Gersoff W. Elsevier Saunders Philadelphia, 2011; 147-160.
9. Nehrer S, Doroška R, Domayer S et al. Treatment of full-thickness chondral defects with hyalograft C in the knee: a prospective clinical case series with 2 to 7 years' follow-up. *Am J Sports Med.* 2009; Nov;37 Suppl 1:81S-87S
10. Vascellari A, Rebutti E, Schiavetti et al. Implantation of matrix-induced autologous chondrocyte (MACI(®)) grafts using carbon dioxide insufflation arthroscopy. *Knee Surg Sports Traumatol Arthrosc.* 2014 Jan;22(1):219-25.
11. Marcacci M, Berruto M, Brocchetta D et al. Articular cartilage engineering with Hyalograft C: 3-year clinical results. *Clin Orthop Relat Res.* 2005; Jun;(435):96-105
12. Della Villa S, Kon E, Filardo G et al. Does intensive rehabilitation permit early return to sport without compromising the clinical outcome after arthroscopic autologous chondrocyte implantation in highly competitive athletes? *Am J Sports Med.* 2010; Jan;38(1):68-77.

Conflict of Interest: NIL
Source of Support: NIL

How to Cite this Article

Brittberg M. Scaffold based autologous chondrocyte implantation: The surgical technique. *Asian Journal Arthroscopy.* Jan-April 2019;4(1):23-26 .