

## HA-BMAC: The Surgical Technique, Pearls and Pitfalls

Katarzyna Herman<sup>1</sup>, Vetri Kumar<sup>1</sup>, Dawid Szwedowski<sup>1</sup>, Luca Chierici<sup>1</sup>, Alberto Gobbi<sup>1</sup>

### Abstract

Articular cartilage is a highly specialized tissue with poor healing potential. Damage to the cartilage following an injury to the joint is prevalent which leads to osteoarthritis. More research is aimed towards tissue regeneration and prevention of degeneration. Efforts to repair and restore the hyaline like cartilage using two-stage procedures such as autologous chondrocyte implantation have led to the development of scaffolds. Bone marrow aspirate concentrate that contains multi potent stem cells which has the potential to differentiate into hyaline like cartilage along with the use of a scaffold is an effective, reliable and single-stage method of cartilage restoration

**Keywords:** cartilage repair, HA-BMAC, bone marrow, scaffold

### Introduction

Articular cartilage in the knee is a highly specialized tissue, not only responsible for load bearing, but also for providing a smooth gliding interface for a joint. Nonetheless, due to the avascular nature of the tissue and specialized cells with low mitotic potential, cartilage has limited healing capacity. As it is well-known that cartilage once damaged does not heal, surgical intervention may be needed to achieve repair of the chondral defects. Failure to obtain good functional outcome can lead to cartilage degeneration, which could subsequently result in development of osteoarthritis (OA) [1,2]. Almost 60% incidence of chondral lesions has been reported in all patients between 40 and 50 years of age [3,4]. Chondral lesions are usually a result of an acute injury or repetitive microtrauma in high impact or cutting sports and are commonly seen along anterior cruciate ligament (ACL) tear [5,6]. What is more, an overuse injury due to limb mal-alignment or joint instability may also lead to cartilage damage [7]. Due to the fact that OA treatment is very complex and expensive [8], it is crucial to treat such injuries early and effectively. Nowadays research is focusing on preventive

interventions and therapeutic solutions that will enhance tissue regeneration and the reduction of degenerative mechanisms [9]. Over the years, a number of techniques in cartilage restoration have been developed in order to prolong the durability of cartilage repair. Autologous chondrocyte implantation (ACI) has shown to stimulate the production of hyaline-like repair tissue, providing longer clinical improvement for the patient [10,11]. Evolution of this technique led to the development and use of scaffolds that allowed cell ingrowth, still that did not eliminate the need for chondrocyte harvest and cultivation. That is why, the idea of performing a single-step procedure to avoid the two-stage surgical procedures led to the use of bone marrow aspirate concentrate (BMAC), that contains multi-potent stem cells (MSCs) and growth factors [12, 13, 14]. MSCs are promising option for cartilage defect repair because of their differentiation potential also towards cartilage [14, 15, 16]. Furthermore, it has been proven that MSCs interact with a non-woven scaffold, the HYAFF 11, that supports cellular adhesion, migration and proliferation and also promotes synthesis and delivery of extracellular matrix components under static

culture conditions [17, 18, 19]. Unlike previous techniques using chondrocyte implantation, MSC isolation does not require healthy cartilage tissue harvesting, so there is no need for cartilage biopsy surgery and subsequent chondrocyte cultivation. Eliminating the need for two surgeries reduces the costs of the surgery by approximately 5 times. Nejadnik et al. compared the clinical results of patients treated with first generation ACI and patients treated with autologous bone marrow derived mesenchymal stem cells (BMSCs), the authors concluded that use of BMSCs in cartilage repair is as effective as chondrocytes for articular cartilage repair, it is also less invasive and reduces costs [20]. In addition, in our study, we compared patients treated with matrix induced autologous chondrocyte implantation (MACI) with patients who have undergone treatment with MSCs combined with the same scaffold. At 3 year follow up we did not notice any statistically significant differences between the two groups and concluded that these techniques were viable and effective [21]. It has been shown in many publications that HA-BMAC technique is a valuable method for treatment of the full thickness cartilage lesions

<sup>1</sup>Orthopaedic Arthroscopic Surgery International (OASI) Bioresearch Foundation, Milan, Italy.

#### Address of Correspondence:

Dr. Alberto Gobbi, MD  
Orthopaedic Arthroscopic Surgery International (OASI) Bioresearch Foundation, Via G.A. Amadeo 24, 20133, Milan, Italy.  
Email: gobbi@cartilagedoctor.it




Dr. Katarzyna Herman



Dr. Vetri Kumar



Dr. Dawid Szwedowski



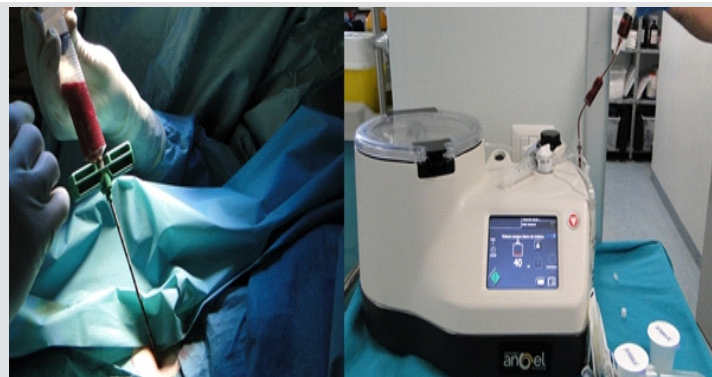Dr. Luca Chierici



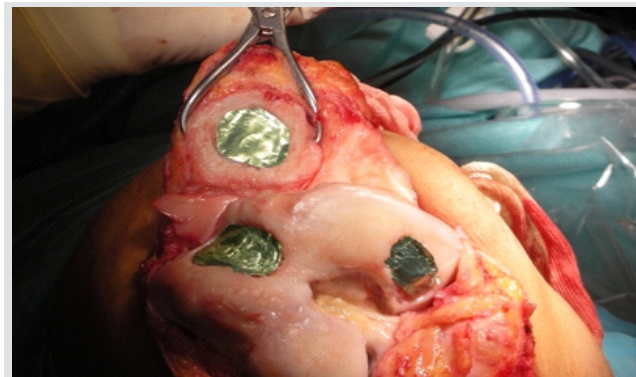
Dr. Alberto Gobbi

© 2019 Herman et al | Asian Journal of Arthroscopy | Available on [www.asianarthroscopy.com](http://www.asianarthroscopy.com) | doi:10.13107/aja.2456-1169.v04i01.008

This is an Open Access article distributed under the terms of the Creative Commons Attribution Non-Commercial License (<http://creativecommons.org/licenses/by-nc/3.0>) which permits unrestricted non-commercial use, distribution, and reproduction in any medium, provided the original work is properly cited.



**Fig 1:** Preparation of Bone marrow aspirate concentrate



**Fig 2:** Intraoperative image of templating the defect using aluminium foil

of the knee, serving as a biological arthroplasty for the treated joint [22, 23]. We have shown that different sizes of cartilage lesions can be treated, not only is it effective for small lesions, but also for multiple and big defects up to 22 cm<sup>2</sup> [24]. Some techniques of cartilage lesion repair emphasize the fact that the age of the patient may affect the outcome, but the HA-BMAC technique has proven to be effective in treatment for patients over 45 years of age [25].

### Indications

Combination of hyaluronic acid (HA) based scaffold and a bone marrow aspirate concentrate (BMAC) is not a universal cure for all damaged joints, but it is extremely effective when applied for a carefully selected group of patients. This procedure is a good solution for cartilage repair for patients less than 60 years of age with body mass index (BMI) less than 30. It is also crucial that all concomitant problems are addressed during the surgery. Malalignment if present, should be corrected at the time of the repair, as well as any kind of ligament instability or meniscal injury. However, this treatment is not indicated in

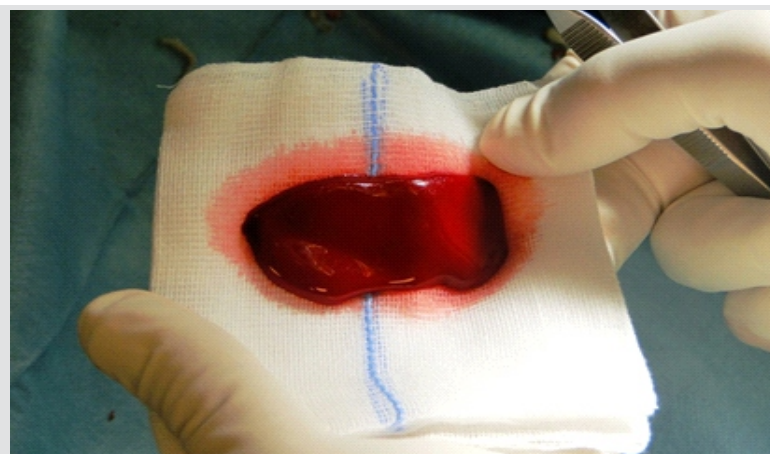
older (>60 yrs), obese (BMI>30) with severe tri-compartmental OA (ICRS Grade 4). Patients with untreated mal-alignment (varus /valgus > 5°) or knee instability and patients who have had multiple intra-articular injections with steroids in the three months preceding the procedure. Hip disorders leading to abnormal gait, general systemic illnesses, such as rheumatic diseases, Bechterew syndrome, chondrocalcinosis, gout and neuro-vascular diseases are also contraindications.

### Surgical technique

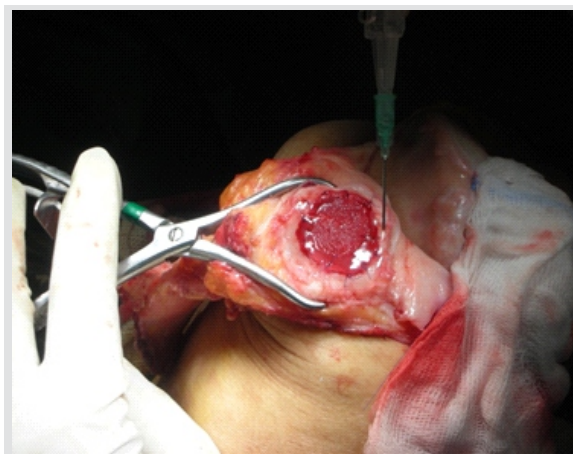The patient is positioned supine for a standard knee arthroscopy. The ipsilateral iliac crest is prepared and exposed for bone marrow aspiration. Whole procedure is performed under general anaesthesia. Examination of the knee under anaesthesia is done to recognize the concomitant pathologies that will be addressed during the procedure. All cartilage lesions are then identified during diagnostic arthroscopy. At this time of the procedure it is necessary to choose whether the procedure will be performed arthroscopically or through

arthrotomy. Arthroscopic intervention is only possible if the lesion can be fully visualised with the arthroscope and reached with instruments, if not the procedure should be continued through arthrotomy. Thorough excision of the loose chondral tissue is necessary, ensuring that the border of the lesion is vertical to the subchondral plane. The calcified cartilage layer overlying the subchondral bone needs to be removed, care must be taken not to violate the subchondral plate.

BMAC preparation is started after the lesion is prepared. Using a dedicated aspiration kit approximately 60 mL of bone marrow from the ipsilateral iliac crest is harvested. The aspirate is centrifuged with a commercially available system to obtain the concentrated bone marrow (Angel, Cytomedix, Gaithersburg, MD)(Fig.1). The dimensions of the lesion have to be measured in order to prepare the matching implant from the three-dimensional hyaluronic acid-based scaffold (Hyalofast, Anika Therapeutics, Srl, Abano Terme, Italy). It is also possible to cut an aluminium foil model before, to check if it fits the lesion and



**Fig 3:** Formation of BMAC clot after activation



**Fig 4:** Intraoperative image of HA-BMAC implanted into the lesion



then cut the scaffold according to the aluminium foil model (Fig.2). When the scaffold is ready, BMAC is activated with batroxobin enzyme (Plateltex Act, Plateltex SRO, Bratislava, Slovakia). Activation process is necessary for BMAC to form a clot which is then applied onto the prepared scaffold forming a sticky implant, that is easy to apply into the lesion (Fig.3).

According to the chosen approach, previously prepared HA-BMAC is then implanted to the lesion. If open technique is chosen the surgeon should apply HA-BMAC directly into the lesion (Fig.4). If needed, fibrin glue is added to further secure the graft. Knee is then flexed and extended to check the graft stability. If the surgeon chooses an arthroscopic approach fluid needs to be completely drained and the lesion should be inspected under arthroscopy after fluid drainage to ensure that circumferential border is stable. The scaffold is introduced into the joint via the working portal through a valveless cannula and using a grasper the implant is placed gently filling the cartilage defect. A hook can be used to press-fit the scaffold into the lesion. The crucial part of the procedure is to check the implant stability. The joint is moved a couple of times while the scaffold is observed with the arthroscope. If needed fibrin glue is applied to improve the implant stability. The working portals are sutured, a drain should not be inserted into the joint [26].

### Postoperative rehabilitation

#### Immediate post-operative protocol at the hospital

First day after the surgery the patient is taught static exercises to prevent vascular complications and muscle hypotrophy. The limb is placed on a continuous passive motion (CPM) machine on a continuous or intermittent basis for the next few days or weeks, the range of motion is set according to the site and size of the lesion. The patient stays in the hospital for approximately three days, where the physiotherapist trains the patient on non-weight bearing crutch assisted walking with a straight leg brace. The brace is to be worn day and night and removed only when doing rehabilitation exercises and during showering.

#### Post-operative rehabilitation protocol

All patients follow a standard rehabilitation protocol after HA-BMAC implantation. However, this programme should be modified

according to the patient's progress and capabilities. The programme is divided into four phases, each phase lasting from six to 12 weeks.

#### I. Proliferative/ Protective Phase (0–6 weeks)

This phase aims to protect the implanted scaffold from excessive loads and shearing forces. The goal for the patient is to gain full extension with gradual recovery of knee flexion by the end of this phase. The patient can start toe touch ambulation by the end of third week and partial weight bearing at sixth week. The brace should be locked at 0 degrees of extension during ambulation and at nights for at least four weeks. Mobilisation may begin at the third week with the aim to achieve flexion of 120 degrees by the end of six weeks. Strengthening exercises should start immediately with static exercises progressing to pool exercises by three weeks and cycling by the end of four weeks. Pain and swelling are controlled with cryotherapy, stockings and anti-inflammatory drugs. Next phase can begin when the patient regains complete passive extension and flexion of approximately 120 degrees with minimum pain, swelling and adequate quadriceps recruitment.

#### II. Transition Phase (6–12 weeks)

After six weeks, gait retraining begins to increase the muscle strength and to gradually increase functional activities. The brace should be maintained until there is sufficient quadriceps strength for ambulation. Full weight bearing without crutches is started eight to twelve weeks post-implantation as tolerated. It is important to start multidirectional patella mobilisation exercises along with active and passive range of motion (ROM) exercises. Next phase of rehab can begin after achieving pain-free full range of motion, about 70% quadriceps and flexor strength compared to contralateral limb and normal gait pattern.

#### III. Maturation Phase (12–24 weeks)

At this period of time, focus is on increasing the quadriceps, flexor strength and resistance, as well as increase in functional activities. Patient can progress to next phase of rehabilitation if 90% quadriceps and flexor strength compared to contralateral limb is achieved.

#### IV. Functional Recovery Phase (24–52 weeks)

During this phase patients gradually return to functional activity without limitations. It involves both closed and open chain exercises with progressive weight bearing and plyometric exercises. The goal of these exercises is to improve patient's

proprioception, agility and coordination, so that patient can safely go back to sporting activities.

### Pearls and Pitfalls of HA-BMAC Cartilage Repair

#### Pearls

- Complete exposure of the cartilage lesion is essential, and may be problematic in the patellofemoral compartment. Use traction methods as needed to provide a comfortable working space.
- If dimensions of the prepared cartilage defect are difficult to measure, use an aluminum foil template or similar material to assist with accurate scaffold size matching.
- The hyaluronic acid-based scaffold composition is symmetrical; after creation of the HA-BMAC graft, implantation may proceed with either side placed against the subchondral bone.

#### Pitfalls

- Arthroscopic cartilage repair should proceed only in cases where the entirety of the defect can be appreciated and treated in a minimally invasive manner; repair should be performed in an open manner otherwise.
- Confirm secure graft seating within the cartilage defect by cycling the knee under arthroscopic visualization; failure to do so may increase the risk of graft delamination in the postoperative period.

## Conclusions & Keypoints

Though there are various methods described to treat cartilage defects, achieving a good long term outcome has always been challenging. It has been proven that full thickness cartilage defects treated with a hyaluronic acid based scaffold embedded with activated bone marrow aspirate concentrate show good to excellent long term outcomes in the treatment of large cartilage defects. Not only is this technique a good solution for younger

patients but also good clinical outcomes can be expected in patients over 45 years of age. Moreover, by eliminating the need for a two staged procedure the cost is reduced and the risk of complications lessened.

## References

- Hunter W. On the Structure and Diseases of Articulating Cartilage. *Philos Trans R Soc Lond B Biol Sci* 1743; 9:277.
- Mankin HJ. The response of articular cartilage to mechanical injury. *J Bone Joint Surg Am*. 1982;64(3):460-6.
- Widuchowski W, Widuchowski J, Trzaska T (2007) Articular cartilage defects: study of 25,124 knee arthroscopies. *Knee*; 14:177-82
- Flanigan DC, Harris JD, Trinh TQ, Siston RA, Brophy RH (2010) Prevalence of chondral defects in athletes' knees: a systematic review. *Med Sci Sports Exerc* 42:1795–1801
- Johnson DL, Urban WP Jr, Caborn DN et al (1998) Articular cartilage changes seen with magnetic resonance imaging-detected bone bruises associated with acute anterior cruciate ligament rupture. *Am J Sports Med* 26:409–414
- Lohmander LS, Roos H, Dahlberg L et al (1994) Temporal patterns of stromelysin-1, tissue inhibitor, and proteoglycan fragments in human knee joint fluid after injury to the cruciate ligament or meniscus. *J Orthop Res* 12:21–28
- Mandelbaum BR, Browne JE, Fu F et al (1998) Articular cartilage lesions of the knee. *Am J Sports Med* 26:853–861
- Kotlarz H, Gunnarsson CL, Fang H, Rizzo JA. Insurer and out-of-pocket costs of osteoarthritis in the US: evidence from national survey data. *Arthritis Rheum*. 2009 Dec;60(12):3546-53.
- Takeda H, Nakagawa T, Nakamura K, Engebretsen L. Prevention and management of knee osteoarthritis and knee cartilage injury in sports. *Br J Sports Med*. 2011 Apr;45(4):304-9. Epub 2011 Feb 25.
- Marcacci M, Berruto M, Brocchetta D, et al. Articular cartilage engineering with Hyalograft(R) C: 3-year clinical results. *Clin Orthop Relat Res* 2005;435:96-105.
- Gobbi A, Kon E, Berruto M, et al. Patellofemoral full-thickness chondral defects treated with second-generation autologous chondrocyte implantation: Results at 5 years' follow-up. *Am J Sports Med* 2009;37: 1083-1092
- Ando W, Tateishi K, Katakai D, et al. In vitro generation of a scaffold-free tissue-engineered construct (TEC) derived from human synovial mesenchymal stem cells: biological and mechanical properties and further chondrogenic potential. *Tissue Eng Part A*. 2008;14(12): 2041-2049.
- Caplan AI. Mesenchymal stem cells: cell-based reconstructive therapy in orthopedics. *Tissue Eng*. 2005;11(7-8):1198-1211.
- Caplan AI. Mesenchymal stem cells: the past, the present, the future. *Cartilage*. 2010;1(1):6-9.
- Dimarino AM, Caplan AI, Bonfield TL. Mesenchymal stem cells in tissue repair. *Front Immunol*. 2013;4:201.
- Huselstein C, Li Y, He X. Mesenchymal stem cells for cartilage engineering. *Biomed Mater Eng*. 2012;22:69-80.
- Pasquinelli G, Orrico C, Foroni L, Bonafè F, Carboni M, Guarnieri C, et al. Mesenchymal stem cell interaction with a non-woven hyaluronan-based scaffold suitable for tissue repair. *J Anat*. 2008;213(5):520-30.
- Lisignoli G, Cristino S, Piacentini A, Zini N, Noël D, Jorgensen C, et al. Chondrogenic differentiation of murine and human mesenchymal stromal cells in a hyaluronic acid scaffold: differences in gene expression and cell morphology. *J Biomed Mater Res A*. 2006;77(3):497-506.
- Facchini A, Lisignoli G, Cristino S, Roseti L, De Franceschi L, Marconi E, et al. Human chondrocytes and mesenchymal stem cells grown onto engineered scaffold. *Biorheology*. 2006;43(3-4):471-80.
- Nejadnik H, Hui JH, Feng Choong EP, Tai BC, Lee EH. Autologous bone marrow-derived mesenchymal stem cells versus autologous chondrocyte implantation: an observational cohort study. *Am J Sports Med*. 2010 Jun; 38(6): 1110-6.
- Gobbi A, Chaurasia S, Karnatzikos G, Nakamura N. Matrix-Induced Autologous Chondrocyte Implantation versus Multipotent Stem Cells for the Treatment of Large Patellofemoral Chondral Lesions: A Nonrandomized Prospective Trial. *Cartilage*. 2015 Apr;6(2):82-97.
- Gobbi A, Karnatzikos G, Sankineani SR. One-step surgery with multipotent stem cells for the treatment of large full-thickness chondral defects of the knee. *Am J Sports Med*. 2014 Mar;42(3):64857.
- Gobbi A et al. Biologic Arthroplasty for Full-thickness Cartilage Lesions of the Knee: Results at Three Years Follow-up (SS-56) *Arthroscopy*, Volume 29, Issue 6, e27
- Gobbi A, Karnatzikos G, Scotti C, Mahajan V, Mazzucco L, Grigolo B. One-Step Cartilage Repair with Bone Marrow Aspirate Concentrated Cells and Collagen Matrix in Full-Thickness Knee Cartilage Lesions: Results at 2-Year Follow-up. *Cartilage*. 2011 Jul;2(3):286-99.
- Gobbi A, Scotti C, Karnatzikos G, Mudhigere A, Castro M, Peretti GM. One-step surgery with multipotent stem cells and Hyaluronan-based scaffold for the treatment of full-thickness chondral defects of the knee in patients older than 45 years. *Knee Surgery, Sports Traumatology, Arthroscopy*. 2017;25(8):2494-2501.
- Whyte GP, Gobbi A, Sadlik B. Dry Arthroscopic Single-Stage Cartilage Repair of the Knee Using a Hyaluronic Acid-Based Scaffold With Activated Bone Marrow-Derived Mesenchymal Stem Cells. *Arthroscopy Techniques*. 2016;5(4):e913-e918.

Conflict of Interest: NIL  
Source of Support: NIL

### How to Cite this Article

Herman K, Kumar V, Szwedowski D, Chierici L, Gobbi A. HA-BMAC: The Surgical Technique, Pearls and Pitfalls. *Asian Journal Arthroscopy*. Jan-April 2019;4(1):34-37.