Review Article
Asian Journal of Arthroscopy | 2020 January-April ; 5(1): 36-42.

Management of the Medial Collateral Ligament in the Combined Ligament Injured Knee

Kyle Borque[1], Mary Jones[2], Andy Williams[2]

Abstract

While isolated medial collateral ligament (MCL) injuries can frequently be treated non-operatively, in the setting of a multiple ligament injured knee, operative intervention is frequently required. The MCL's biomechanical roles (primary restraint to valgus, secondary restraint to internal and external tibial rotation) must be taken into account when addressing the injured MCL. The authors prefer a combination of repair and reconstruction, with the goal of preserving proprioceptive feedback while also restoring mechanical support. The ideal surgical technique depends on the acuity and location of the injury. The goal of this paper is to provide a framework for approaching both operative and nonoperative treatment of MCL injuries in the setting of multiple ligament knee injuries.

Keywords: Medial collateral ligament (MCL), Knee dislocation, Multiple ligament knee injury, MCL repair, MCL reconstruction

Introduction

Whilst in the context of the isolated ligament injury a vast majority of medial collateral ligament (MCL) tears can be managed non-surgically [14,23,26,27], in the combined ligament injured knee that may or may not have dislocated, MCL injuries often need surgery. The MCL is the primary resistor of valgus stress and also, as is often forgotten, a significant resistor of external tibial rotation and internal tibial rotation [28]. The superficial MCL spans the medial side of the knee and provides the most restraint to valgus load. The deep MCL is particularly important in resisting external rotation and the posterior oblique capsular thickening aids in resisting internal rotation of the tibia in the knee close to extension.

An isolated ligament injury in the context of a combined ligament injury to the knee is a very different scenario, even for the ligament concerned. As load is transmitted to the joint, structures fail sequentially and the soft tissue envelope effectively 'unzips' as the structures yield. Therefore each component of a combined ligament injury does not behave simply as an isolated ligament rupture. Whilst with isolated MCL injuries some residual ligament laxity is well tolerated when neuromuscular control is optimized, even minor excess laxity related to the MCL injury can be problematic in the knee with a combined ligament injury. Any excess laxity will tend to add load and therefore increase the risk of failure of reconstructed cruciate ligament grafts [5,24,33]. In one recent study from Sweden, non-operative treatment of MCL injuries in the setting of ACL reconstruction was a potent driver of anterior cruciate ligament (ACL) graft failure [31].

For approximately 20 years, the senior author provided a service of treatment in combined ligament injury cases in the Southeast of England. Despite keeping good data, unfortunately it has not been possible to achieve a quality evidence-base, even with extensive experience in specialist centres. The main reason for this is the heterogeneity of the injury patterns. The combinations of injuries vary considerably as there are ligament complexes medially and laterally to be considered as well as additional injury to chondral surfaces and menisci and the patellofemoral joint. In addition, nerve and vascular injuries change prognosis. The situation is made even more complex with the evolution over time of optimal treatment. As a result, even with a very large number of cases and quality data for the individual cases, a meaningful statistical interpretation of results is usually impossible. Many lessons can be learned nevertheless, but it has to be accepted that the nature of this article, like so many others on this topic, is experientially based rather than truly evidence based.

The important principles of treating the combined ligament injured knee are obtaining and maintaining congruent reduction of the joint, re-establishing ligamentous stability, and achieving early motion.

First aid

In the context of a combined ligament injury, possible knee dislocation should never be discounted. This can occur even with a two ligament injury. In all cases, the joint should be reduced (if not already spontaneously reduced as the majority are) and reduction held with splintage such as a brace. In cases of uncontrolled instability, which is often associated with accompanying fractures, an external fixator may be required. In addition, proper evaluation of neurovascular status is also mandatory. It is our practice to undertake angiography to assess for vascular damage, though ankle brachial blood pressure monitoring has been shown to be a viable alternative [21].

Very much specific to the medial soft tissue envelope, some dislocations are impossible to reduce closed due to the medial femoral condyle prolapsing through a rent in the MCL/medial soft tissue envelope. The hallmark of the 'button holed' medial femoral condyle is a sulcus sign in which the soft

[1]Department of orthopaedics, Houston Methodist Hospital, Houston, TX, USA.
[2]Department of orthopaedics, Fortius Clinic, London, UK.
Address of Correspondence
Dr. **Kyle Borque**,
Houston Methodist Hospital, Houston, TX, USA.
E-mail: kaborque@gmail.com


Dr. Kyle Borque


Dr. Mary Jones


Dr. Andy Williams

Picture 1: Medial transverse skin rupture from an extreme valgus mechanism

Figure 2: 16 year old female softball player with an ACL rupture and tibial avulsion of the MCL, with grade III laxity

tissues on the medial side of the joint below the femoral condyle are pulled laterally. This creates a dimple effect. In extreme cases of valgus displacement, a transverse rupture of the skin will be seen (as in picture 1). This is often misinterpreted as a laceration due to something cutting the skin rather than a

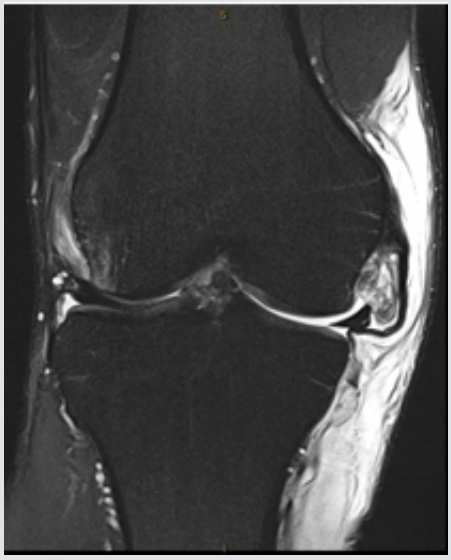

Figure 3: Distal MCL avulsion that has flipped into the joint

Figure 1: A-C. (A) shows the classic maneuver to test valgus laxity. In the setting of ACL deficiency, the tibia will translate anteriorly, due to the effect of gravity on the femur / thigh, which can tighten slack soft tissues and provide a false sense of MCL competency. (B and C) show the importance of supporting the distalfemur (right hand), allowing the tibia to fall posteriorly with gravity to reduce the joint while apposing the medial and lateral femoral condyles on the tibia with axial compression (with the left hand).

rupture of the skin from stretching. This obviously represents an open dislocation and therefore the potential risk of contamination of the joint and infection is much higher. This needs to be treated with urgent open reduction and irrigation of the joint in the operating room.

Clinical evaluation

In the acute setting, a combined ligament injury must be suspected in a knee that has laxity in multiple planes and frequently little intra-articular swelling. The rupture of the soft tissue envelope allows extravasation of fluid/blood and therefore less evidence of effusion. With time, bruising will appear on the medial side of the knee.

Clinical evaluation of knee ligament laxity and examination is difficult when there are a number of ligaments involved. It is very easy to achieve spurious conclusions. In the acute setting pain may limit the ability of the patient to relax and hamper examination. Nevertheless, with patience and a gentle approach, important information can be found.

It is always helpful to have information about the mechanism of injury. Whilst combined ligament injury can be associated with a high degree of violence such as with motorcycle injuries, this is not always the case. Unfortunately in the West, knee dislocations occur in the morbidly obese from as little as a minor stumble [22].

Usually valgus plus external rotation are the injurious forces causing MCL damage. In a posteriorly directed force on the tibia, as well as stress on the PCL, the posterior obliquecapsule/posteromedial corner of the knee can be injured.

The most important aspect of knee examination in cases of combined ligament injury is to start with the knee in a reduced position. For example, if there is ACL laxity and the examiner uses the classic examination technique (seen in Figure 1A) of holding the proximal leg with both hands with the patient's foot/ankle wedged between the examiner's arm and torso, due to the affect of gravity on the femur, the tibia will subluxan teriorly immediately. This may artificially tension the MCL and so tension pathologic laxity in the collateral ligaments thereby leading to a false sense of MCL competence. On the contrary, in a PCL deficient knee using the method described above to examine the collateral ligaments will allow the tibia to reduce on the femur. Therefore if there is ACL deficiency present or a bi-cruciate injury, it is best to support the distal femur (or in the latter case proximal tibia and distal femur) with the examiner's hand placed around the lateral side of the joint to the popliteal fossa region and the other hand of the examiner holding the foot and moving the knee into varus/(as seen in Fig. 1 B and C). In all cases, before testing varus and

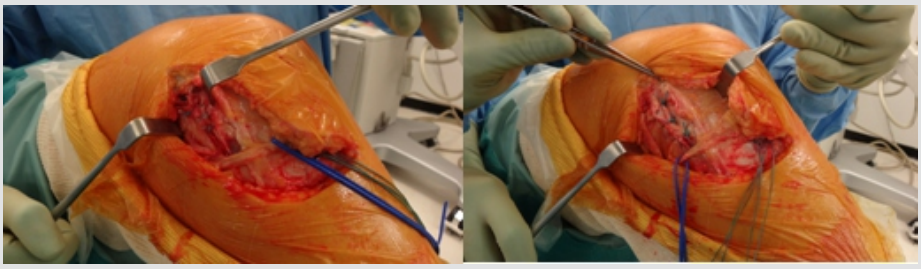

Picture 2: In 2A, the deep MCL (layer 3) has been repaired and re-tensioned with figure of eight sutures. In 2B the superficial MCL, which was previously split to access the deep MCL is re-tensioned by use of 'double-breasting' 'pants over vest' suture technique.

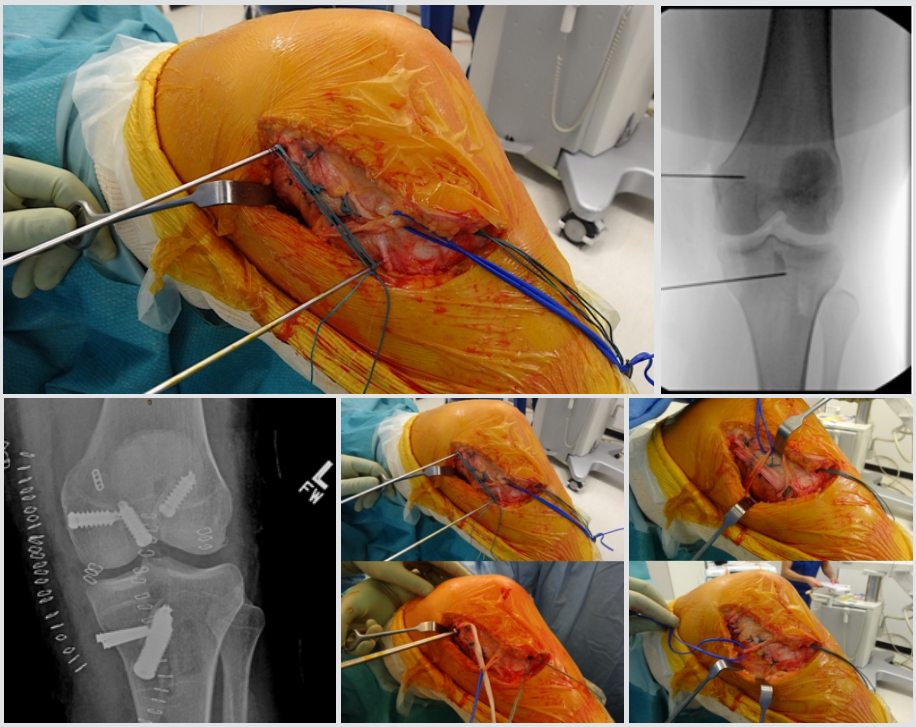

Picture 3: show the progression of an MCL reconstruction. First clinical and fluoroscopic views of pins placed with suture to assess isometry. Also seen is a branch of the infrapatellar branch of the saphenous nerve which is protected with a vessel loop. Next a suture is tied around the pins and brought the full range of motion to confirm isometry. The synthetic ligament is then fixed in the femur with an interference screw then on the tibia with two staples. Lastly, layer 1 deep fascia is closed on top of the synthetic ligament to prevent irritation of the nerve superficial to layer 1.

Figure4: shows immediate post-operative radiographs from a bicruciate plus MCL reconstruction- note the relatively short length of the MCL construct.

valgus to assess the collateral ligaments it is essential that the examiner has provided some axial compression on the joint so that both femoral condyles are in contact with their corresponding tibial surfaces, which ensures neutral axial rotation.

In addition to valgus instability related to MCL insufficiency, rotational tests must also be undertaken. Failure of the MCL (specifically deep MCL) is one cause of a positive 'dial test'. A positive dial test in which there is an excess of more than 5^0 side to side difference is recognised as being caused by posterolateral rotatory insufficiency from an injury to popliteus complex [19]. This is particularly so at 30^0. At 90^0 it can be related to combined posterolateral corner and PCL insufficiency. In the posterolateral corner related and PCL related increase in external rotation, the lateral tibia moves posteriorly. Equally an increase in external rotation can occur from anteromedial rotatory instability in which the medial tibial condyle moves anteriorly [8]. To differentiate the medial from lateral causes of this phenomenon, it is essential that the examiner carefully observes the movement of the proximal medial tibia as well as the posterolateral tibia when performing the dial test.

In most cases posteromedial rotatory insufficiency is hard to detect, but an internal rotation 'dial test' can sometimes reveal this. This is performed similarly to the classical external rotation dial test, except that internal rotation, not external rotation, of the tibia is assessed.

If associated ACL involvement is present then with the knee at 90^0 flexion having established a positive anterior drawer, the tibia should be externally rotated. If the MCL (specifically deep MCL) is competent then the external rotation applied will tighten the medial soft tissue and abolish the anterior drawer. If, however, the anterior drawer persists with the tibia in external rotation, it implies there is failure of the MCL (specifically deep MCL).

There are a number of ways of grading valgus laxity. The first classification was released by the American Medical Association [30], which was subsequently modified by Hughston to the most commonly utilized system now [15]. The severity (graded I-III) is based on the amount of fibers torn. Laxity (grade 1+, 2+ or 3+) is based on the amount of excess opening to valgus stress at 30^0 of flexion compared to the contralateral side. Grade 1+ represents up to 5 mm of increased opening while grade 3+ is more than 10 mm increased opening. Many examiners find it hard to be accurate regarding the amount of excess opening they produce with clinical examination. Stress radiographs (e.g. Telos instrumentation) can provide an accurate measurement of excess joint opening [17]. The normal and injured knee can be compared but the reproducibility depends highly on skilled technicians ensuring that limb placement is not only symmetric but in the correct plane[16]. Stress radiographs are rarely possible in the acute setting due to pain. The more practical grading system is the following [12]. Grade 0 is an injury to the ligament without excess laxity. 0-5mm opening with a good end feel indicates Grade I. Grade II is up to 10mm of excess opening compared with the opposite knee but with an end feel. Grade III laxity is opening with an excess of 10mm compared with the other side and with a soft or imperceptible end feel. When valgus laxity is assessed, the knee should be at 30^0, so that the posterior capsule is relaxed and therefore the MCL itself is specifically examined. If MCL laxity is detected then a valgus stress should be applied with the knee in full extension. If the knee then opens to any degree medially, this must indicate an injury to the posteromedial corner of the knee. This may well involve the posterior cruciate ligament.

Finally, evaluation of stability of the patellofemoral joint is critical as in severe medial soft tissue envelope injuries the patella can dislocate laterally due to disruption of its restraining medial soft tissue structures. The best way to do this is to have the knee flexed 20^0-30^0 over the examiner's knee and for the patella to be pushed medially and then laterally with care so as not to injure the patient and to

assess relative translation and the potential for apprehension.

Imaging

All complex knee injuries require x-ray examination. Bony avulsions can be associated with MCL injury and most commonly this involves the femoral attachment site but can involve the tibial site. In chronic MCL injuries, heterotopic ossification can occur with a classic Pellegrini-Stieda lesion forming[6].

On MRI scanning a more detailed evaluation of the ligament is possible. Deep, superficial and posterior oblique portions can be identified separately by good radiologists and knee surgeons. The value of the MRI scan is to determine what is injured. The experience of the senior author is that the severity of clinical laxity rarely correlates with the severity of MRI abnormality. In determining appropriate treatment, only the clinical grading is of value in his experience. Nevertheless, certain findings can immediately point to surgery such as an MCL that has folded into the joint between the femoral and tibial condyles (usually under the medial meniscus surface) or a pattern of injury analogous to a Stener lesion of the ulnar collateral ligament of the thumb in which the MCL pulls off the tibia distally and comes to lie superficial to the pes anserine tendons [1]. Although one would think it inevitable that surgery be required for such lesions and it usually is the senior author has had a number of cases whereby the knee was re-scanned for various reasons days after the initial injury and the lesions were found to have spontaneously reduced with the MCL back deep to the pes tendons!

Another value of MRI is to assess other injuries present such as the result of compression of the lateral compartment with meniscal tears, osteochondral lesions or even fractures. In addition, as described above, patellar dislocation can be associated with a major MCL injury in the context of a combined ligament injury of the knee. If fracture is thought to be present then CT scan should be attained.

Management of isolated MCL injuries

As previously mentioned, the vast majority of isolated MCL injuries can be successfully treated non-operatively. For an isolated MCL rupture of Grade 0 or I no bracing is used. For Grade II and Grade III laxities a brace is applied and weight bearing modified. The regimen is two weeks non-weight bearing with a range of 30^0-60^0 followed by two weeks partial weight bearing with the brace set 10^0-90^0. This is followed by a final two weeks of full weight bearing with the brace on free range. It is important to instruct the patient to ambulate in the first 6 weeks with the foot pointing straight ahead to avoid external rotational torque (see above) which can stretch out the MCL. Applying these restrictions to MCL injuries in a combined ligament injury, however, is usually harmful to the patient as they rarely restore range of movement following the four weeks of restricted motion. In the context of a combined ligament injury, should bracing be undertaken then full active and passive extension should be achieved as soon as possible in most cases. If there is excess hyperextension then the knee should be brought close to symmetry with the opposite knee but the posterior capsule allowed to heal by not forcing hyperextension. Flexion over 60^0 tends to tighten/stress the PCL and therefore it is wise to restrict flexion to 60^0 if there is a PCL injury for two weeks and 90^0 for a further two weeks. Weight bearing should be restricted, as described above, for the isolated injury.

Adjuvant injection treatment with PRP has been advocated by some [4,7,32] and even prolotherapy [25]. In combined ligament injuries, adjuvant injection is completely unnecessary due to the huge inflammatory/healing response generated by such major injuries.

Management of MCL in the context of a combined ligament injury

Appropriate treatment is evolving. 20-30 years ago most combined ligament injuries involving the MCL were treated with acute surgery [2,10], or casting, but it was noted that results of this were poor due to loss of range of motion and persistent MCL laxity[13]. Stiffness occurs due to the large surface area of the medial ligament complex and the complexity of the alignment and bony attachment sites of the various components of this ligamentous complex. One of the problems 20-30 years ago with acute repair was simply related to the ignorance of surgeons regarding this complex anatomy. Anatomic knowledge has hugely improved since then but is not entirely clarified [18,28].

This led to a period in which it was felt best to brace the MCL, in an effort to allow it to heal, and then undertake a delayed ACL reconstruction plus MCL reconstruction if necessary [3,9,29]. The concept was that this led to better results with lower complications (particularly less stiffness) and that in any case a late MCL reconstruction was just as good as early surgery. What this approach ignores is that repair of the MCL as opposed to reconstruction, is far more likely to result in closer to normal proprioceptive feedback, which will optimise the quality of the long term result. It is easy for orthopaedic surgeons to only think about the mechanical restraint of ligaments and not consider the huge role in helping coordinate neuromuscular control via their proprioceptive feedback. Nevertheless, the desire to maximise proprioception by undertaking early MCL repair needs to be balanced against the significant risk of stiffness. Whilst for most combined ACL/MCL injuries, delayed ACL reconstruction after allowing the MCL to heal with bracing remains the most sensible option, in certain patient populations, such as elite athletes, this is not the case. A period of bracing leads to loss of bone density and neuromuscular control during the non-operative period thereby compromising the fixation and healing of an ACL graft as well having reduced quality of fixation of MCL graft. In addition, elite athletes are abnormally tough, have better access to rehabilitation and thus have less problems with stiffness following acute surgery to both the cruciate and MCL.

Nevertheless, the senior author finds he does less acute MCL repair/reconstruction in the context of combined ligament injuries than previously. This is due to the advent of good PCL directed braces that can allow combined PCL/MCL injuries to heal and sometimes not even require surgery (Jack PCL Brace, Albrecht Funktionelle Rehabilitation, Bernau, Germany).

Selection of patients and timing of surgery

There has been a period of 'heroic' surgery for knee dislocations with the evangelical belief that early surgery to deal with all abnormal ligament laxities/injured structures gave the best results. This can be appropriate but frequently leads to significant complications. The senior author currently undertakes less acute MCL surgery and more staged surgeries, even in cases where early surgery (such as a posterolateral corner injury) demand an early operation on another part of the knee.

The goal of surgical treatment for MCL injury is to provide stability and function in cases of chronic symptomatic laxity or in acute cases where a bad outcome is likely/inevitable with non-operative treatment. In addition, due to abnormal kinematics and joint loading

secondary to MCL laxity, the potential for reduced osteoarthritic risk should be considered.

The following cases have high rates of poor outcomes with non-operative treatment and require surgery:

- Grade III MCL laxity with a tibial avulsion pattern.
- Cases of MCL avulsion from the tibia in which the superficial MCL lies superficial to the pes anserine tendons–the MCL 'Stener lesion'.
- Cases in which the MCL has infolded into the joint.
- Cases of irreducible dislocation with 'button holing' for the medial femoral condyle through the soft tissue envelope.
- Combined PCL/MCL injuries in which the PCL lesion is Grade III (with a reversed medial tibial step off) and an MCL laxity of Grade II or III.
- Bi-cruciate ruptures with Grade II to III PCL laxity and Grade II or III MCL laxity. In these cases an ACL reconstruction can be delayed until the joint is 'quiet' and mobile at around three to four months after initial surgery for PCL/MCL.

An important principle of combined ligament surgery is to understand when early surgery has to be done. In the acute setting, the surgery is difficult, the tissues swollen and prolonged operations in this situation have increased risk of infection (which is a disaster) and loss of range of movement. For the ACL component there is no hurry as delayed reconstruction yields good results even after other structures have been operated upon. There seems to be good evidence that early surgery is required for posterolateral injuries and usually this is combined with a reconstruction to protect the anatomic repair achieved [11]. On the other hand, many MCL injuries and PCL injuries in the context of a combined ligament injury can at least be initially treated non-surgically due to the quality of modern bracing (see above). If the fibres of the medial structures are relatively well aligned with their bony attachment sites, even with up to grade II PCL laxity results with the use of a PCL directed brace can be excellent.

The real controversy really relates to ACL plus MCL injury. The majority of these are relatively low violence and frequently occur in skiing injuries. In most patients these are appropriately initially treated with bracing and non-operative management before later surgery if required. In the elite athlete, however, an acute ACL reconstruction around three weeks from injury when full active extension, a minimum flexion of 100^0 and a 'quiet' knee has been achieved is appropriate. The MCL will be repaired and reconstructed if there is Grade II or more laxity.

Lastly, it is often said that tibial avulsion injuries of the MCL, which are less common than femoral sided injuries, have a poor prognosis and require surgery. Whilst the senior author would agree that more of these injuries do lead to chronic laxity problems, the need for surgery is rather less than has been suggested. The knee can often be treated appropriately with bracing, and later re-evaluation.

Acute surgery

The goal of surgery is to provide stable congruent reduction of the joint (in this case the medial compartment +/- patellofemoral joint) with sufficient robustness that full extension can be achieved immediately postoperatively and flexion can be unrestricted. As stated above, the physical examination determines the degree of laxity and thus the need for surgery, while the preoperative MRI scan can be helpful to identify the pathoanatomy so that an operative plan can be achieved. The author's preference is for anatomic repair of injured structures with sutures/anchors to bony attachment points and reconstruction at the same time to protect the anatomic repair.

On the approach, wherever possible the infrapatellar branch of saphenous nerve and its branches are identified, dissected free and protected throughout the procedure (as can be seen in picture 3). This can greatly improve sensation on the front of the knee and shin. To do so requires adequate exposure through a relatively large medial wound.

In the acute setting, bony landmarks are less required as it is usually obvious if surgery is undertaken within two weeks from injury where attachment sites of avulsed tissues are. When the MCL repair is undertaken, it is essential that the tibia is reduced on the femur. In the sagittal plane this means that if a PCL reconstruction or repair is required then it should be undertaken first to bring the tibia forward onto the femur in the appropriate position and negate the effect of gravity on the leg. Once the anteroposterior position has been set then the MCL can be repaired with appropriate soft tissue tensioning. Considering the effect of gravity, an ACL reconstruction is not absolutely necessary before fixing the MCL and can be delayed if preferred.

As well as the position of the tibia on the femur in the sagittal plane, it is essential to think about the rotational alignment. Great care must be taken to ensure that the tibia is in a natural 'neutral' rotational position with the foot 10^0 externally rotated in a normal 'progression angle' for gait. The flexion angle for tightening the ligaments is important. The MCL (deep and superficial) is of most importance at 30^0 knee flexion and should be sutured in this position. The posterior oblique ligament/capsule (POL) can be avulsed (usually from the femur) and is naturally tight in extension. Therefore the sutures should be tightened to repair this ligament with the knee at 10^0 flexion.

A reconstruction (see later) is always added to protect the repair. The author's preference is to use synthetic material (i.e. a prosthesis or tape) attached to the femur and tibia. This is placed over the superficial MCL repair and deep to Layer 1 which is closed superficial to the synthetic material.

There is currently popularity in using a percutaneous approach with small incisions to allow subcutaneous routing of synthetic tape between the femur and tibia to provide temporary stabilisation of the medial compartment and allowing the soft tissue envelope to spontaneously heal. Whilst the senior author may use synthetic tape for reconstruction, he strongly believes that a formal open approach to surgery is preferable to allow for a proper anatomical repair to be completed at the same time, provide accurate placement of the synthetic material and avoid injuring the branches of the saphenous nerve as described above. Sadly he has had experience of cases sent to him with significant harm being done by such percutaneous techniques.

If a patellar dislocation has occurred then direct repair of the medial soft tissues can sufficee specially if there is no patella-femoral dysplasia. Rarely the senior author will undertake an MPFL reconstruction using a gracilis tendon if the medial retinacular tissues /MPFL are irreparable or if there is patella-femoral dysplasia.

Chronic MCL laxity surgery

The principle in these cases is to achieve re-tensioning of the native healed but lax tissue and then protect these re-tensioning procedures with reconstruction. The first step is identifying the location of the laxity-above or below the meniscus. This is done with the

help of pre-operative MRI and confirmed intra-operatively.

If the laxity is found to be above the meniscus (at arthroscopy the joint will be seen to open above the meniscus when valgus stress is applied) then a layer by layer dissection can be used to effectively allow a 'capsular shift' type procedure to be undertaken. Layer 1 (deep fascia) is incised longitudinally from the epicondylar region of the femur to just distal to the meniscus. Next an incision is made from the femoral attachment point of the MCL down to the level of meniscus in Layer 2 (superficial MCL). Usually with careful sharp dissection it is possible to separate Layer 3 (deep MCL) from Layer 2. The deep MCL can be re-tensioned by using 'figure of eight' plicating sutures to shorten the ligament. Alternatively a suture anchor placed at the femoral attachment of the deep MCL and a Kessler-type suture can achieve the same result. Next, not only is Layer 2 double-breasted over Layer 3, it can be drawn proximally towards its femoral attachment again using a number of interrupted 'figure of eight' sutures. Usually three or four of these sutures are required. Similar sutures can be used in the posteromedial capsular region/POL region to achieve its desired result but rather than being tightened with the knee at 30^0 it should be tightened with the knee at 10^0 as described above.

For lesions affecting the distal MCL (the meniscus will be seen to pull away from the tibia as valgus force is applied during arthroscopic examination) the situation is a little more complex. Here the superficial MCL is identified through the exposure from splitting Layer 1. The superficial MCL should be split with a vertical incision leaving an anterior and posterior half on the tibia. These two limbs are elevated from their tibial attachment and the bone thus exposed, curetted or drilled in places to create the potential for healing. A non-absorbable heavy suture is taken up the anterior or posterior limb in a Kessler fashion with locking bites and then down the other limb. The two suture ends are then fixed with a suture anchor into the tibia. This can be undertaken to recreate the natural proximal attachment of the MCL around approximately 2 cm below the joint line and again around 6 cm below the joint line [18]. The split in the superficial MCL is then double breasted to tighten the construct further. Fixation is undertaken with the knee at 30^0 flexion with neutral rotation, as described above.

MCL reconstruction

As already stated in the introduction of this article, the senior author believes the MCL is the hardest knee ligament to successfully reconstruct. Graft choice is of relevance. Soft tissue grafts tend to stretch with early mobilisation and his dissatisfaction with them means that his preference is to now to use synthetic grafts. If the injury and laxity are relatively minor (grades I and II) this can simply be a doubled synthetic tape linked by femoral and tibial suture anchors. In a more extensive case (grade III laxity) it involves the use of a substantial synthetic structure. Because synthetic grafts are unyielding, it is absolutely essential that attachment points are accurately and carefully chosen. The graft used need to be isometric for the superficial and deep MCL components.

The senior author's approach to MCL reconstruction could be considered to be unusual. Generally speaking, with the advancement of ligament surgery, the closer that reconstructions have got to natural anatomy the better the results. We may, however, be arriving at a point where sometimes non-anatomic but biomechanically sound constructs are preferable. There are well documented 'anatomic' techniques [20], but unfortunately these have obvious weaknesses. If suture fixation of the graft more proximally on the tibia works, surely the graft distal to this point is surplus to requirement. On the other hand, if a suture fixation to the natural proximal attachment of the superficial MCL on the tibia yields, the working length of the graft is greatly lengthened and with the elasticity of soft tissue (be it allograft or autograft) significant graft lengthening and medial opening of the joint will occur. In addition, should the proximal tibial fixation fail, leaving only the distal fixation on the tibia, there will be very little rotatory control.

The anatomic structure responsible for external rotation control is largely the deep MCL [28]. The senior author therefore prefers to undertake a reconstruction that effectively restores the deep MCL. This means that there is a relatively short graft and, as a result, the graft provides stiffness that controls valgus as well as external and internal rotation. A posterior oblique ligament reconstruction is therefore rarely indicated. Indeed it is only required in a minority of PCL + MCL reconstructions.

Bony landmarks are certainly important and the first priority is exposure of the femoral bony landmarks including adductor tubercle and medial epicondylar region. The latter is relatively difficult to palpate with certainty as it is over a fairly large area and therefore fluoroscopy should be used in all cases to identify the appropriate femoral attachment point. From the femoral attachment, as well as passing distally, the deep MCL and to a lesser extent the superficial MCL pass anteriorly. There is therefore an obliquity to the construct required.

Whilst individual fibres within the MCL complex are not truly isometric, a reconstruction graft must be placed in an isometric position. Therefore with fluoroscopy, two guide pins are placed in the desired attachment points, just posterior and proximal to the medial epicondyle on the femur and at the centre of the MCL on the tibia 2-3 cm below the joint line. A suture is then connected between the two pins and the knee taken through a range of motion to assess the isometry (as can be seen in picture 3). Adjustments to the pin placement, particularly on the femur, are usually required to optimise this. Once isometry is confirmed, either synthetic tape and two suture anchors, or a synthetic prosthesis with a tunnel proximally with interference screw fixation and distal double stapling are used. The synthetic material is placed deep to the infrapatellar branch of the saphenous nerve. It is required to utilize fluoroscopy to ensure, not only ideal femoral and tibial attachments but to ensure that no staples / anchors violate the joint.

Postoperative management

In the context of combined ligament injury, the PCL will always dominate if injured or reconstructed. The rehabilitation specific to the MCL emphasises full active extension as soon as possible. Passive extension should allow the knee to come into early hyperextension (but no more). Flexion can increase as tolerated with a goal of at least 90^0 at two to three weeks from surgery. Weight bearing is limited to two weeks of non-weight bearing followed by two weeks of partial weight bearing. Other lesions such as meniscal repairs or chondral surgery may dictate a different weight bearing regime.

References

1. Alaia E, Rosenberg Z, Alaia M. Stener-Like Lesions of the Superficial Medial Collateral Ligament of the Knee: MRI Features. Am J Roentgenol. 2019;213(6):W272-W276.
2. Andersson C, Gillquist J. Treatment of acute isolated and combined ruptures of the anterior cruciate ligament: A long-term follow-up study. Am J Sports Med. 1992;20(1):7-12. doi:10.1177/036354659202000103.
3. Azar F. Evaluation and treatment of chronic medial collateral ligament injuries of the knee. Sport Med Arthrosc Rev. 2006;2:84-90.
4. Bagwell MS, Wilk KE, Colberg RE, Dugas JR. the Use of Serial Platelet Rich Plasma Injections With Early Rehabilitation To Expedite Grade Iii Medial Collateral Ligament Injury in a Professional Athlete: a Case Report. Int J Sports Phys Ther. 2018;13(3):520-525. doi:10.26603/ijspt20180520.
5. Battaglia MJ, Lenhoff MW, Ehteshami JR, et al. Medial collateral ligament injuries and subsequent load on the anterior cruciate ligament: A biomechanical evaluation in a cadaveric model. Am J Sports Med. 2009;37(2):305-311. doi:10.1177/0363546508324969.
6. Coltart W. Pellegrini-Stieda lesion. Proc R Soc Med. 1938;31(03):180-181.
7. Eirale C, Mauri E, Hamilton B. Use of platelet rich plasma in an isolated complete medial collateral ligament lesion in a professional football (soccer) player: A case report. Asian J Sports Med. 2013;4(2):158-162. doi:10.5812/asjsm.34517.
8. Engebretsen L, Lind M. Anteromedial rotatory laxity. Knee Surg Sport Traumatol Arthrosc. 2015;23(10):2797-2804.
9. Fanelli GC, Edson C. Arthroscopically assisted combined anterior and posterior cruciate ligament reconstruction in the multiple ligament injured knee: 2- to 10-year follow-up. Arthroscopy. 2002;18(7):703-714.
10. Fetto J, Marshall J. Medial collateral ligament injuries of the knee: a rationale for treatment. Clin Orthop Relat Res. 1978;132:206-218.
11. Geeslin A, LaPrade RF. Outcomes of treatment of acute grade-III isolated and combined posterolateral knee injuries: a prospective case series and surgical technique. J Bone Jt Surg Am. 2011;93(18):1672-1683.
12. Harner C, Buoncristiani A, Tjoumakaris F. Master Techniques in Orthopaedic Surgery: Reconstructive Knee Surgery. Third ed. Lippincott, Williams & Wilkins Inc; 2008.
13. Harner CD, Irrgang JJ, Paul J, Dearwater S, Fu FH. Loss of motion after anterior cruciate ligament reconstruction. Am J Sports Med. 1992;20(5):499-506. doi:10.1177/036354659202000503.
14. Holden DL, Eggert AW, Butler JE. The nonoperative treatment of Grade I and 11 medial collateral ligament injuries to the knee. Am J Sports Med. 1983;11(5):340-344. doi:10.1177/036354658301100511.
15. Hughston J. The importance of the posterior oblique ligament in repairs of acute tears of the medial ligaments in knees with and without an associated rupture of the anterior cruciate ligament. Results of long-term follow-up. J Bone Jt Surg Am. 1994;76(9):1328-1344.
16. Kennedy J, Fowler P. Medial and anterior instability of the knee. An anatomical and clinical study using stress machines. J Bone Jt Surg Am. 1971;53(7):1257-1270.
17. LaPrade RF, Bernhardson AS, Griffith CJ, MacAlena JA, Wijdicks CA. Correlation of valgus stress radiographs with medial knee ligament injuries: An in vitro biomechanical study. Am J Sports Med. 2010;38(2):330-338. doi:10.1177/0363546509349347.
18. LaPrade RF, Engebresten A, Ly T, Johansen S, Wentorf F, Engebretsen L. The anatomy of the medial part of the knee. J Bone Jt Surg Am. 2007;89(9):2000-2010.
19. LaPrade RF, Terry GC. Injuries to the Posterolateral Aspect of the Knee. Am J Sports Med. 1997;25(4):433-438. doi:10.1177/036354659702500403.
20. Laprade RF, Wijdicks CA. Development of an anatomic medial knee reconstruction. Clin Orthop Relat Res. 2012;470(3):806-814. doi:10.1007/s11999-011-2061-1.
21. Levy BA, Fanelli GC, Whelan DB, et al. Controversies in the treatment of knee dislocations and multiligament reconstruction. J Am Acad Orthop Surg. 2009;17(4):197-206. doi:10.5435/00124635-200904000-00001.
22. Lian J, Patel N, Nickoli M, et al. Obesity Is Associated with Significant Morbidity after Multiligament Knee Surgery. J Knee Surg. 2019;10:1055/s-0039-1681027.
23. Lundberg M, Messner K. Long-term prognosis of isolated partial medial collateral ligament ruptures: A ten-year clinical and radiographic evaluation of a prospectively observed group of patients. Am J Sports Med. 1996;24(2):160-163. doi:10.1177/036354659602400207.
24. Mancini EJ, Kohen R, Esquivel AO, Cracchiolo AM, Lemos SE. Comparison of ACL Strain in the MCL-Deficient and MCL-Reconstructed Knee during Simulated Landing in a Cadaveric Model. Am J Sports Med. 2017;45(5):1090-1094. doi:10.1177/0363546516685312.
25. Maor D, Jones M, Lee J, Dunn A, Williams A, Calder J. Prolotherapy as a treatment choice for lateral ankle ligament injuries in elite athletes: A case series. Act Orthop Belgica. 2020;Accepted f.
26. Marchant MH, Tibor LM, Sekiya JK, Hardaker WT, Garrett WE, Taylor DC. Management of medial-sided knee injuries, part 1: Medial collateral ligament. Am J Sports Med. 2011;39(5):1102-1113. doi:10.1177/0363546510385999.
27. Reider B, Sathy MR, Talkington J, Blyznak N, Kollias S. Treatment of Isolated Medial Collateral Ligament Injuries in Athletes with Early Functional Rehabilitation: A Five-year Follow-up Study. Am J Sports Med. 1994;22(4):470-477. doi:10.1177/036354659402200406.
28. Robinson JR, Sanchez-Ballester J, Bull AMJ, Thomas R de WM, Amis AA. The posteromedial corner revisited. An anatomical description of the passive restraining structures of the medial aspect of the human knee. J Bone Jt Surg - Ser B. 2004;86(5):674-681. doi:10.1302/0301-620X.86B5.14853.
29. Shirakura K, Terauchi M, Katayama M, Watanabe H, Yamaji T, Takagishi K. The management of medial ligament team in patients with combined anterior cruciate and medial ligament lesions. Int Orthop. 2000;24(2):108-111. doi:10.1007/s002640000119.
30. Standard Nomenclature of Athletic Injuries. In: American Medical Association, Subcomittee on Classifcation of Sports Injuries. ; 1966.
31. Svantesson E, Hamrin Senorski E, Alentorn-Geli E, et al. Increased risk of ACL revision with non-surgical treatment of a concomitant medial collateral ligament injury: a study on 19,457 patients from the Swedish National Knee Ligament Registry. Knee Surgery, Sport Traumatol Arthrosc. 2019;27(8):2450-2459. doi:10.1007/s00167-018-5237-3.
32. Yoshioka T, Kanamori A, Washio T, et al. The effects of plasma rich in growth factors (PRGF-Endoret) on healing of medial collateral ligament of the knee. Knee Surgery, Sport Traumatol Arthrosc. 2013;21:1763-1769.
33. Zhu J, Dong J, Marshall B, Linde M, Smolinski P, Fu F. Medial collateral ligament reconstruction is necessary to restore anterior stability with anterior cruciate and medial collateral ligament injury. Knee Surg Sport Traumatol Arthrosc. 2018;26:550-557.

Conflict of Interest: NIL
Source of Support: NIL

How to Cite this Article

Borque K, Jones M, Williams A | Management of the Medial Collateral Ligament in the Combined Ligament Injured Knee | Asian Journal of Arthroscopy | January-April 2020; 5(1): 36-42.