

Biomechanics and Management of HAGL Lesions in Anterior Instability

Desmond J Bokor¹, Yuval Arama¹

Abstract

Humeral avulsion of the glenohumeral ligament is an uncommon but important cause for recurrent anterior instability of the shoulder. It is usually associated with high energy trauma in a slightly older male population with a hyperabduction/axial load mechanism. Associated damage can include avulsion of the glenoid labrum, rotator cuff tears, and bony damage. Diagnosis requires a high index of clinical suspicion, and MR arthrography performed 4-6 weeks post injury is the most reliable investigation. Care should be taken with MRI performed in the first week, as many of the lesions seen at this time will heal. Surgical repair is recommended for recurrent instability or if the patient requirements need them to have a stable shoulder. Repair can be performed using arthroscopic, minopen or full open techniques. Care should be taken when placing sutures through the capsule because of the proximity of the axillary nerve to the inferior capsular edge. Biomechanically, the capsule should be repaired to the medial humeral neck just below the chondral margin. Surgical outcomes are satisfactory in most series reported.

Keywords: Anterior instability, humeral avulsion of the glenohumeral ligament

Introduction

Damage to the glenohumeral joint structures as a consequence of traumatic anterior instability of the shoulder includes a combination of both ligamentous and bony structures. While the majority of unstable shoulders will have a classical Bankart lesion being either bony or soft tissue, a smaller number of patients will suffer an avulsion of the glenohumeral ligaments from the lateral humeral neck. The first description of the lesion was by Nicola in 1942 [1] with the next significant attention to the lesion by Wolf et al. in 1995 where they initially termed the lesion a "Humeral avulsion of the glenohumeral ligament" [2]. They also noted that this lesion could occur in association with avulsion of a small bony fragment from the medial humerus. The incidence of HAGL has been variably reported as being between 1% and 9% [2-5]. These lesions can occur in combination with a Bankart lesion in a number of cases, and this is often referred to

as the "floating anterior band" [3,6,7]. Other associated injuries include rotator cuff tears in 23% and Hill-Sachs defects in 17% [4]. While numerous other authors have since reported their personal experiences with small case series [6-8], Bokor et al. reported on 41 consecutive cases and noted that it had an incidence of 7.5% in their series of anterior dislocations [3]. They noted that the lesion was more common in males and associated with a violent injury with a large proportion of their patients being rugby players. The average age of the HAGL patients was 27.1 years compared to the general instability cohort average age of 22.7 years.

Biomechanics and Mechanism

The superior middle and inferior glenohumeral ligaments (IGHL) are the primary capsular stabilizers that prevent dislocation of the shoulder. Turkel et al. [9] have shown that these have a variable contribution to overall joint stability

depending on the angle of abduction (0, 45° and 90°) in external rotation. As a consequence of forces applied to the shoulder in these arcs, anterior instability occurs with predominantly avulsion of the anterior and inferior glenoid labrum from the glenoid. Biomechanical studies have demonstrated that with increasing stress/load, the IGHL will undergo strain/deformation and ultimate failure which can occur at the glenoid (40%), within the capsule (35%) or at the humeral attachment (25%) [10].

Studies looking at the pathology found that arthroscopy following a first time instability have demonstrated the Bankart lesion as the main finding [11,12]. Capsular tears were also noted in some series however correlation with an exact mechanism was not clear. Nicola [1] first described the possible mechanism to create an HAGL as hyperabduction with external rotation of the humeral head forcing the head into the inferior glenohumeral pouch. With increasing hyperabduction, the head is levered out of the joint with consequent tearing of the capsule usually from the humeral attachment. If an axial load is also applied at the same time, the head is driven down onto the inferior labrum tearing this off the glenoid at the same time to create the "floating anterior band" (Fig. 1). Further studies by Gagey et al. confirmed that hyperabduction of the humerus with an axial load resulted in predominantly capsular tearing off the humerus but also created the same spectrum of associated

¹Department of Orthopaedic Surgery, Faculty of Medicine and Health Sciences, Macquarie University, Sydney, Australia

Address of Correspondence:

Desmond Bokor, Suite 303, 2 Technology Place, Macquarie University, NSW. 2019, Sydney, Australia.
E-mail: desbok@iinet.net.au



Dr. Desmond J Bokor



Dr. Yuval Arama

© 2017 by Asian Journal of Arthroscopy | Available on www.asianarthroscopy.com | doi:10.13107/aja.2454-5473.149

This is an Open Access article distributed under the terms of the Creative Commons Attribution Non-Commercial License (<http://creativecommons.org/licenses/by-nc/3.0>) which permits unrestricted non-commercial use, distribution, and reproduction in any medium, provided the original work is properly cited.

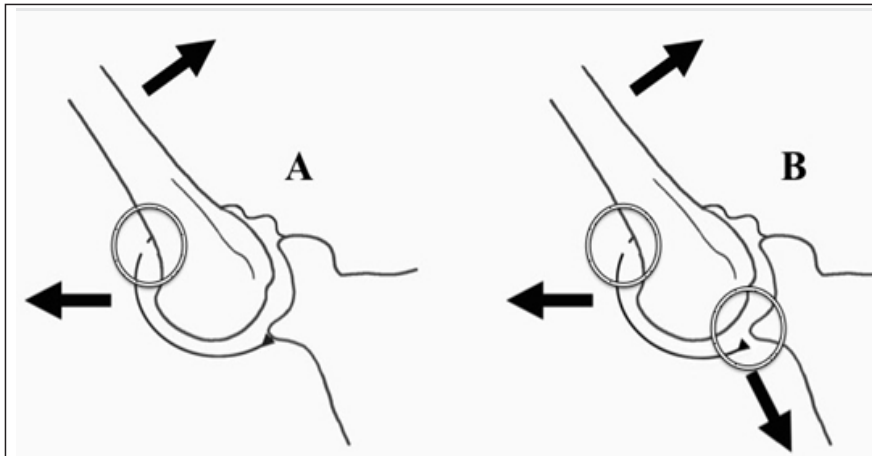


Figure 1: EHumeral avulsion of the glenohumeral ligament lesion with hyperabduction forcing head into inferior pouch. (a) Increasing external rotation levers humeral head out of joint with consequent capsular tearing, (b) hyperabduction with external rotation and axial load drives head onto inferior glenoid rim creating a combined humeral avulsion of the glenohumeral ligament and Bankart lesion

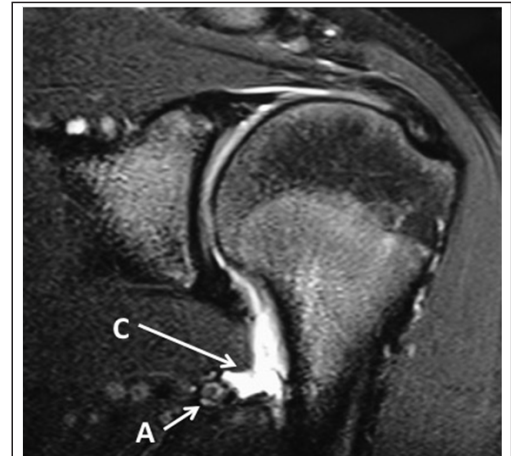


Figure 2: Magnetic resonance arthrogram demonstrating humeral avulsion of the glenohumeral ligament lesion with axillary neurovascular structures -A, in close proximity to the free inferior capsular edge -C

injuries reported in other studies including labral and rotator cuff tears [13]. A more recent study simulated instability by sequential division of the humeral sided capsule demonstrated that extensive capsule-labral tearing is required before dislocation will occur [14]. This, however does not always correlate with the character and size of capsular tears encountered at the time of surgery.

Investigation

The clinical presentation of patients with anterior instability secondary to HAGL may not provide obvious indicators of the specific pathology. A careful history focusing on the position of the arm at time of dislocation, and the violent character of the injury may suggest capsular injury. Patients with a HAGL may have more anterior shoulder pain than the typical instability patient [15]. Gagey has reported that strain elongation and damage to the IGHL may result in increased hyperabduction of the shoulder compared to the opposite side [16].

The plain radiographs in some cases may show a small bony avulsion from the medial humeral neck. Otherwise further investigation will be required to image the capsular damage. While arthrography alone may demonstrate a tear in some cases, it is best combined with CT scanning or MR to better image the capsular tears (Fig. 2). The accuracy of MRI, however, is still controversial with a number of case reports of false-positive imaging of suspected

HAGL lesions [17].

The best timing for plain MRI or MR arthrography (MRA) looking for the HAGL was investigated by Liavaag et al. [18]. They found that over two-thirds of the HAGL lesions and IGHL capsular tears seen on initial MRI (mean 7 days post injury) had healed on subsequent MR arthrogram at a mean 30 days after injury. They felt that the clinical relevance of pathological findings within the capsular ligaments seen on initial MRI should be interpreted with caution and recommended a follow-up MR arthrogram 2-month later before making a decision regarding surgical intervention.

The definitive investigation is arthroscopy of the glenohumeral joint with evaluation of the entire capsule as well as the labrum, rotator cuff, and chondral surfaces. At arthroscopy, the two characteristic findings are the ability to visualize the subscapularis through the avulsed capsule [2] and the disruption of the inferior wave-like attachment of the IGHL to the humerus as seen from the posterior portal [3].

Management

The first line management of patients with anterior instability secondary to a HAGL lesion is physiotherapy and activity modification. The natural history and the likelihood of failure of conservative management and further instability have not been documented for patients with a HAGL as distinct from the general instability population. For those patients with recurrent instability or a functional

requirement for a stable shoulder, surgical correction is recommended.

Early studies of the anatomy of attachment of the IGHL onto the humeral neck suggested two distinct patterns of attachment. The capsule either attached to the juxtachondral edge or in a “V” pattern onto the humeral neck, with the distribution being in equal proportions [19] (Fig. 3). Subsequent dissection by Pouliart and Gagey demonstrated that the true functional capsular insertion was the “V” attachment of the neck of the humerus and the juxtachondral attachment was a capsular recess filled with tissue they described as “frenula capsulae” [20]. Further work by Southgate et al. in a cadaveric biomechanical study using six degrees of freedom jig, confirmed that restoration of the “normal” glenohumeral joint laxity after simulated HAGL lesions and repair was best achieved with attachment of the capsule approximately 10mm below the chondral neck onto the medial humeral neck [21]. Surgical repair of the capsular lesion has been recommended, and this can be performed through arthroscopic, miniopen or full open techniques. Open surgical repair involves a deltopectoral approach with exposure of the subscapularis. Often the inferior muscular component has some scarring from the earlier traumatic injury [3]. After blunt dissection of the subscapularis off the capsule, the tear can be identified (Fig. 4). The capsule often has a thickened rolled edge and care is necessary to dissect this free with identification and

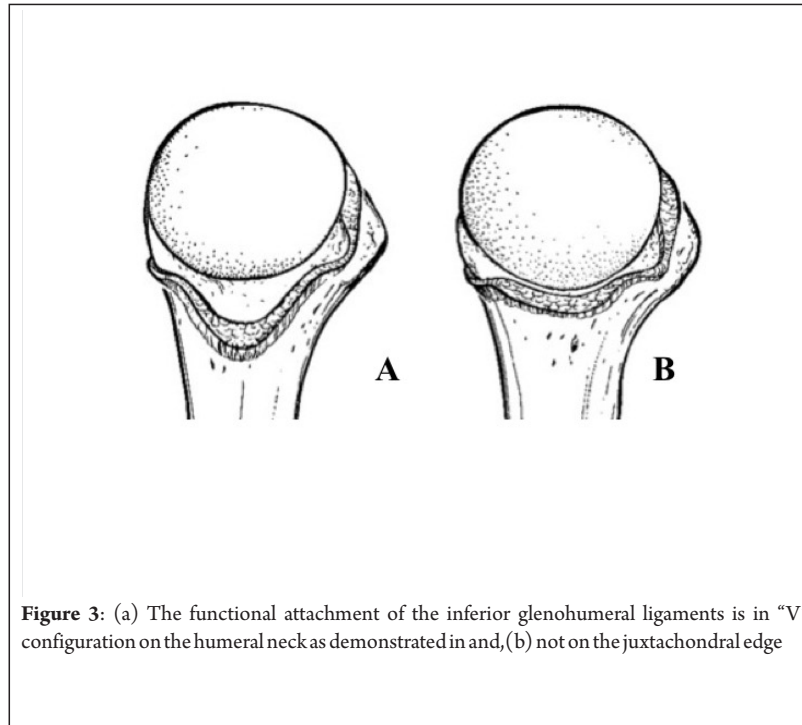


Figure 3: (a) The functional attachment of the inferior glenohumeral ligaments is in "V" configuration on the humeral neck as demonstrated in and, (b) not on the juxtachondral edge

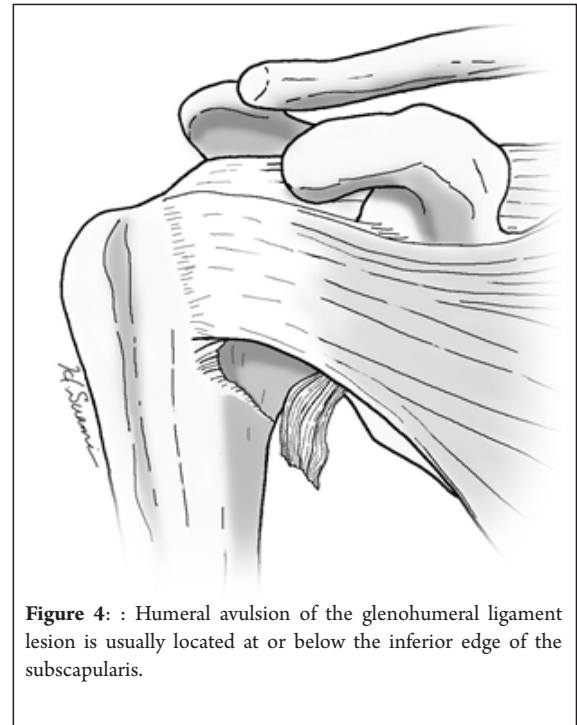


Figure 4 : Humeral avulsion of the glenohumeral ligament lesion is usually located at or below the inferior edge of the subscapularis.

protection of the axillary nerve that is often very closely situated to the capsular edge. The capsule should be attached to the medial humeral neck about 10mm below the chondral edge either with anchors or transosseous sutures through bone tunnels. Arciero and Mazzocca proposed a mini-open repair of the HAGL lesion with an open surgical approach using an "L" shaped incision in the lower portion of the subscapularis muscle with the reflection of the lower muscle fibers to expose the capsular tear [22]. The advantage here is that the upper portion of the subscapularis is not divided and preservation of strength is maintained during the post-operative period. Other authors have suggested that simply elevating the inferior border of subscapularis with careful identification of the axillary nerve can also offer adequate exposure to repair the HAGL lesion to the medial humeral neck [23]. Bhatia and Das Gupta proposed managing HAGL lesions associated with significant anterior glenoid bone loss of <20% with a combined medial subscapularis splitting approach to correct the Bankart lesion and secure the coracoid transfer (Latarjet) and a "lateral subscapularis window" retracting the subscapularis fibers superiorly and repairing the HAGL lesion below this with anchors [24]. Arthroscopic repair has been recommended

by a number of authors more recently and can be performed in both the beach chair and lateral decubitus positions [25-28]. Careful portal placement is an essential and often an anteroinferior trans-subscapularis portal placed 1cm inferior to the upper border of the subscapularis tendon may be necessary for instrumentation. Alternatively, the axillary pouch portal (Bhatia portal) will give good access to the inferior portion of the capsular lesion [29]. This portal is introduced approximately 3cm inferior to the posterolateral acromial border and 2 cm lateral to the routine posterior viewing portal and angled 30° medially to the axial plane. The capsular edge is cleared and mobilized and the medial humeral neck roughened with either a burr or rasp. Sutures are placed at 5 o'clock and 7 o'clock

positions within the capsular avulsion, and these sutures are extended anteriorly as necessary. Due to the close proximity of the axillary nerve to the capsule at the 6 o'clock position, it is not recommended that any sutures be placed here. The arm will then need to be gently mobilized and placed into abduction and external rotation to achieve the necessary angle for insertion of the bone anchors [15]. The capsule is anchored to the humerus and routine anterior reconstruction postoperative protocols are used.

Outcomes

Most reported series of HAGL repair are <10 cases with a medium duration of follow-up. Success in stabilizing the joint is high however, the authors do not discuss in

Table 1: Reported surgical outcomes for humeral avulsion of the glenohumeral ligament repair

Author	Number of cases	Duration of follow-up (months)	Failures	Arthroscopic vs.open
Field et al.	5	26	Nil	Open
Rhee et al.	6	39	Nil	Open (5)
Kon et al.	3	16	Nil	Arthro
Bahtia et al.	7	20	Nil	Mini-open (with latarjet)
Wolf et al.	6	40	Nil	Arthro 4, open 2

detail the level of return to activities especially high collision environments (Table 1). Regardless of the technique used to repair the lesion, the surgeon should be aware that the lesion is a "high energy" injury and most patients want to return to the index environment that leads to their initial dislocation. Hence, the most important surgical determinant the clinician also needs to consider is the "resilience" of that repair for the patient.

Conclusions

The HAGL lesion is an uncommon but important cause for recurrent anterior instability of the shoulder. Recognition requires a high index of suspicion especially in the slightly older individual with a high energy traumatic dislocation with the arm forced into hyperabduction. Imaging is best done with MRA performed at least 30 days after injury to avoid false positive results. Surgical treatment is anatomic repair of the capsular avulsion using arthroscopic, mini-open or full open techniques. Care is needed to identify and protect the axillary nerve that lies in close proximity to the free capsular edge. Surgical outcomes in the limited number of small case series have excellent results.

References

- Nicola T. Anterior dislocation of the shoulder: The role of the articular capsule. *J Bone Joint Surg Am* 1942;24:614-616.
- Wolf EM, Cheng JC, Dickson K. Humeral avulsion of glenohumeral ligaments as a cause of anterior shoulder instability. *Arthroscopy* 1995;11:600-607.
- Bokor DJ, Conboy VB, Olson C. Anterior instability of the glenohumeral joint with humeral avulsion of the glenohumeral ligament. A review of 41 cases. *J Bone Joint Surg Br* 1998;81-B:93-96.
- Bui-Mansfield LT, Banks KP, Taylor DC. Humeral avulsion of the glenohumeral ligaments: The HAGL lesion. *Am J Sports Med* 2007;35(11):1960-1966.
- Bui-Mansfield LT, Taylor DC, Uhorchak JM, Tenuta JJ. Humeral avulsions of the glenohumeral ligament: Imaging features and a review of the literature. *AJR Am J Roentgenol* 2002;179(3):649-655.
- Field LD, Bokor DJ, Savoie FH. Humeral and glenoid detachment of the anterior inferior glenohumeral ligament: A cause of anterior shoulder instability. *J Shoulder Elbow Surg* 1997;6:6-10.
- Rhee YG, Cho NS. Anterior shoulder instability with humeral avulsion of the glenohumeral ligament lesion. *J Shoulder Elbow Surg* 2007;16:188-192.
- Bach BR, Warren RF, Fronek J. Disruption of the lateral capsule of the shoulder. A cause of recurrent dislocation. *J Bone Joint Surg Br* 1988;70:274-276.
- Turkel SJ, Panio MW, Marshall JL, Girgis FG. Stabilizing mechanisms preventing anterior dislocation of the glenohumeral joint. *J Bone Joint Surg Am* 1981;63-A:1208-1217.
- Bigliani LU, Pollock RG, Soslowky LJ, Flatow EL, Pawluk RJ, Mow VC. Tensile properties of the inferior glenohumeral ligament. *J Orthop Res* 1992;10(2):187-197.
- Norlin R. Intraarticular pathology in acute, first-time anterior shoulder dislocation: An arthroscopic study. *Arthroscopy* 1993;9:546-549.
- Baker CL, Uribe JW, Whitman C. Arthroscopic evaluation of acute initial anterior shoulder dislocations. *Am J Sports Med* 1990;18(1):25-28.
- Gagey O, Gagey N, Boisrenoult P, Hue E, Mazas F. Experimental study of dislocations of the scapulohumeral joint. *Rev ChirOrthopReparatriceAppar Mot* 1993;79:13-21.
- Pouliart N, Gagey O. Simulated humeral avulsion of the glenohumeral ligaments: A new instability model. *J Shoulder Elbow Surg* 2006;15:728-735.
- George MS, Khazzam M, Kuhn JE. Humeral avulsion of glenohumeral ligaments. *J Am AcadOrthopSurg* 2011;19:127-133.
- Gagey OJ, Gagey N. The hyperabduction test. An assessment of the laxity of the inferior glenohumeral ligament. *J Bone Joint Surg Br* 2000;82-B:69-74.
- Melvin JS, Mackenzie JD, Nacke E, Sennett BJ, Wells L. MRI of HAGL lesions: Four arthroscopically confirmed cases of false-positive diagnosis. *AJR Am J Roentgenol* 2008;191:730-734.
- Liavaag S, Stiris MG, Svenningsen S, Enger M, Pripp AH, Brox JI. Capsular lesions with glenohumeral ligament injuries in patients with primary shoulder dislocation: Magnetic resonance imaging and magnetic resonance arthrography evaluation. *Scand J Med Sci Sports* 2011;21:e291-e297.
- O'Brien SJ, Neves MC, Arnoczky SP, Rozbruch SR, Dicarlo EF, Warren RF, et al. The anatomy and histology of the inferior glenohumeral ligament complex of the shoulder. *Am J Sports Med* 1990;18:449-456.
- Pouliart N, Gagey O. Reconciling arthroscopic and anatomic morphology of the humeral insertion of the inferior glenohumeral ligament. *Arthroscopy* 2005;21:979-984.
- Southgate DF, Bokor DJ, Longo UG, Wallace AL, Bull AM. The effect of humeral avulsion of the glenohumeral ligaments and humeral repair site on joint laxity: A biomechanical study. *Arthroscopy* 2013;29(6):990-997.
- Arciero RA, Mazzocca AD. Mini-open repair technique of HAGL (humeral avulsion of the glenohumeral ligament) lesion. *Arthroscopy* 2005;21:1152.
- Bhatia DN, DeBeer JF, van Rooyen KS. The "subscapularis-sparing" approach: A new mini-open technique to repair a humeral avulsion of the glenohumeral ligament lesion. *Arthroscopy* 2009;25:686-690.
- Bhatia DN, DasGupta B. Surgical treatment of significant glenoid bone defects and associated humeral avulsions of glenohumeral ligament (HAGL) lesions in anterior shoulder instability. *Knee Surg Sports TraumatolArthrosc* 2013;21:1603-1609.
- Kon Y, Shiozaki H, Sugaya H. Arthroscopic repair of a humeral avulsion of the glenohumeral ligament lesion. *Arthroscopy* 2005;21:632.
- Page RS, Bhatia DN. Arthroscopic repair of humeral avulsion of glenohumeral ligament lesion: Anterior and posterior techniques. *Tech Hand Up ExtremSurg* 2009;13(2):98-103.
- Richards DP, Burkhart SS. Arthroscopic humeral avulsion of the glenohumeral ligaments (HAGL) repair. *Arthroscopy* 2004;20 Suppl 2:134-141.
- Spang JT, Karas SG. The HAGL lesion: An arthroscopic technique for repair of humeral avulsion of the glenohumeral ligaments. *Arthroscopy* 2005;21:498-502.
- Bhatia DN, de Beer JF. The axillary pouch portal: A new posterior portal for visualization and instrumentation in the inferior glenohumeral recess. *Arthroscopy* 2007;23:1241, e1-e5.

Conflict of Interest: NIL
Source of Support: NIL

How to Cite this Article

Bokor DJ, Arama Y. Biomechanics and management of HAGL lesions in Anterior Instability. *Asian Journal of Arthroscopy* Jan - April 2017;1(2):36-39.